



## MOP "MASSAGGIO OLISTICO POSTURALE"

E' una tecnica che viene eseguita manualmente, attraverso tecniche di massaggi che si intersecano e che agiscono secondo la necessità del tessuto cutaneo, connettivale e tendineo muscolare; un'innovazione che porta riscontri positivi anche in presenza di dolori articolari.

Questa tecnica è stata studiata e messa a punto ormai da 30 anni di esperienza e la nostra clientela, sempre più crescente, non riesce a credere che un semplice massaggio possa essere così efficace e con riscontri positivi ma soprattutto veloci; infatti già dalla prima seduta si può verificare un sostanziale miglioramento.

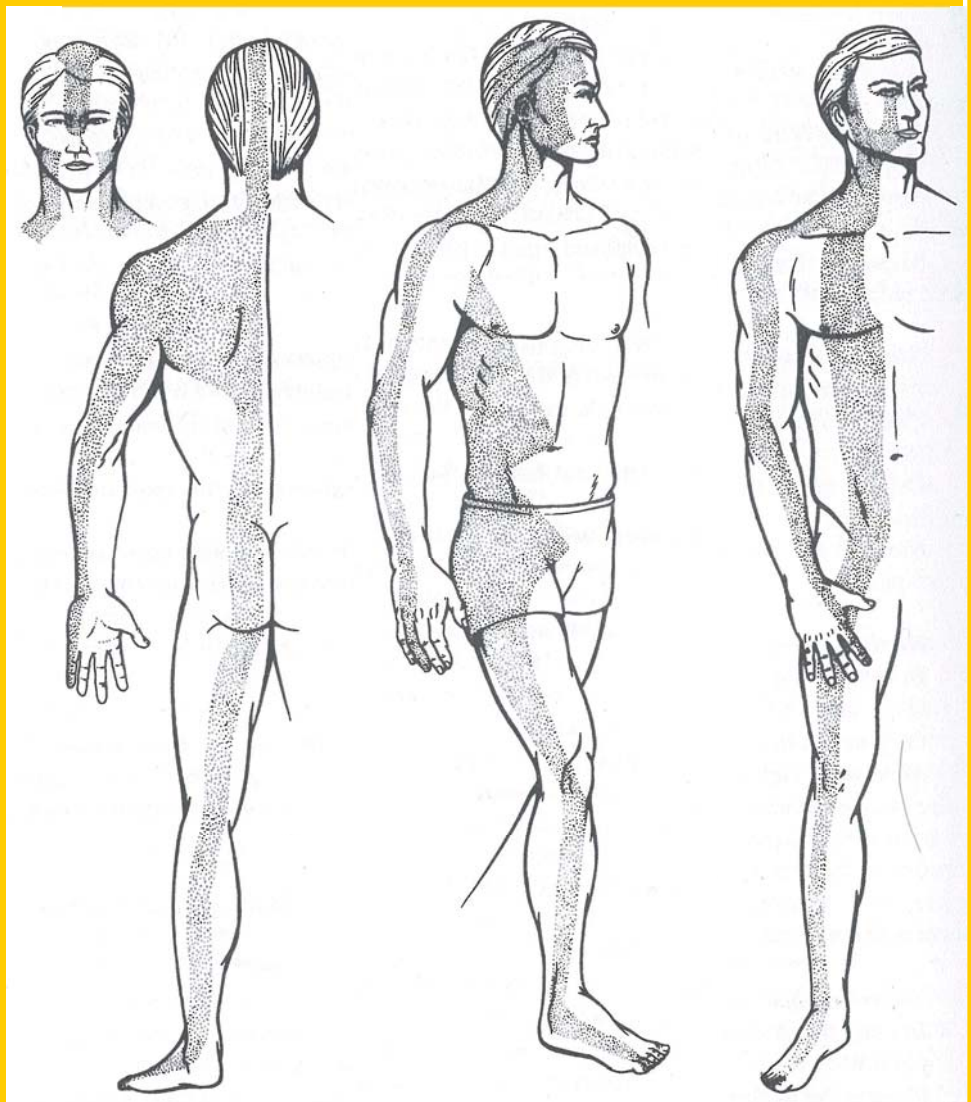
Nelle pagine successive, troverete delle immagini divise in diverse sezioni del corpo, immagini che indicano, il tendine contratto con dei punti in rosso che **crea il dolore** e altre immagini che invece indicano il **propagarsi del dolore**.

### ECCO LE PROSPETTIVE DEL NOSTRO CORPO

Qualora, con la nostra valutazione posturale, riscontriamo un dolore o sul tendine o sul suo modo di propagarsi, siamo certi di poterlo risolvere.

Buoni risultati si possono ottenere anche con pochissime sedute a seconda della gravità del disturbo; possono occorrere, dalle tre al massimo dieci sedute, affinché possiate riscontrare l'esito positivo del trattamento eseguito.

Gli Operatori Specializzati dello studio "MOP centro Massaggio Olistico Posturale", sono pronti a garantire il proprio operato anche attraverso riscontri clinici.

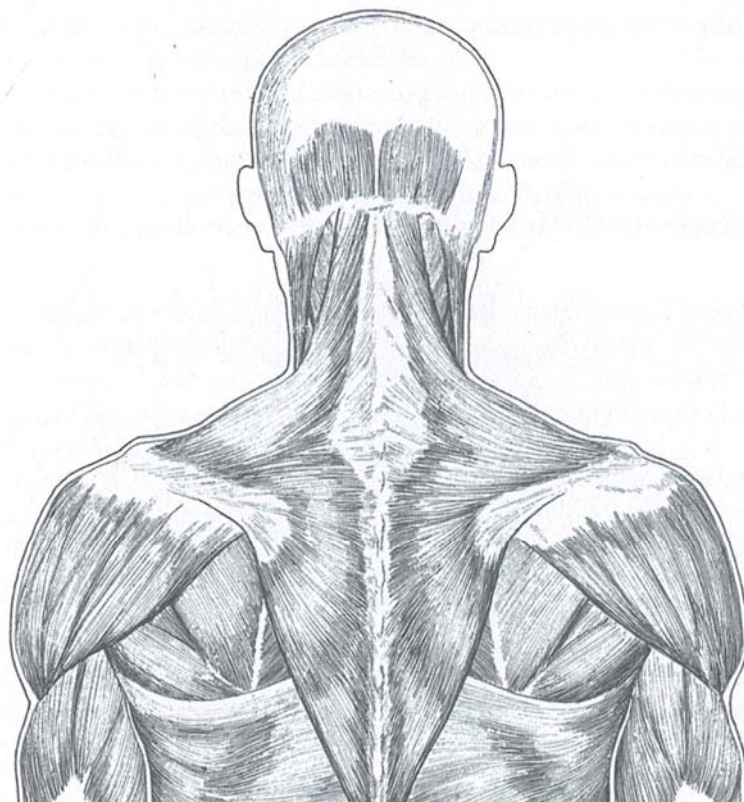


ZONA DORSALE

ZONA LATERALE

ZONA VENTRANA

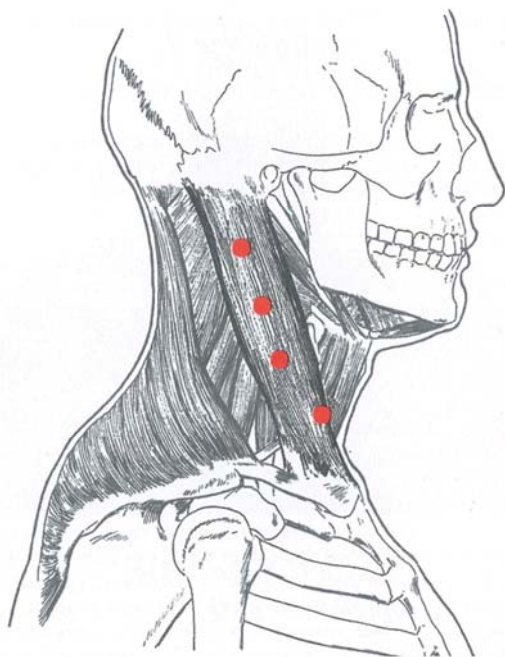
## Tutti i tendini e muscoli della testa, del collo. e del viso



Se nel controllare le immagini successive, constaterete il punto di dolore evidenziato in rosso, il nostro metodo in questo caso è in grado di debellare il vostro dolore.

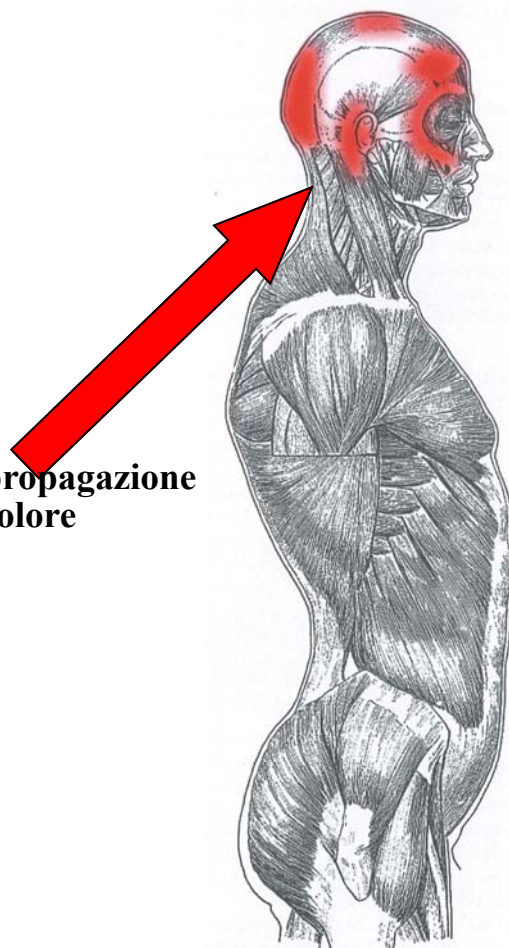
Ogni punto evidenziato in rosso, la tecnica MOP interviene con applicazioni mirate e specifica.

**sternocleidomastoideo**

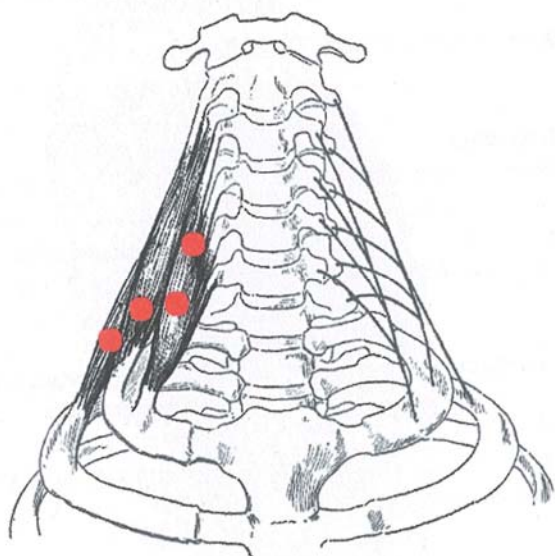


**Il tendine contratto**

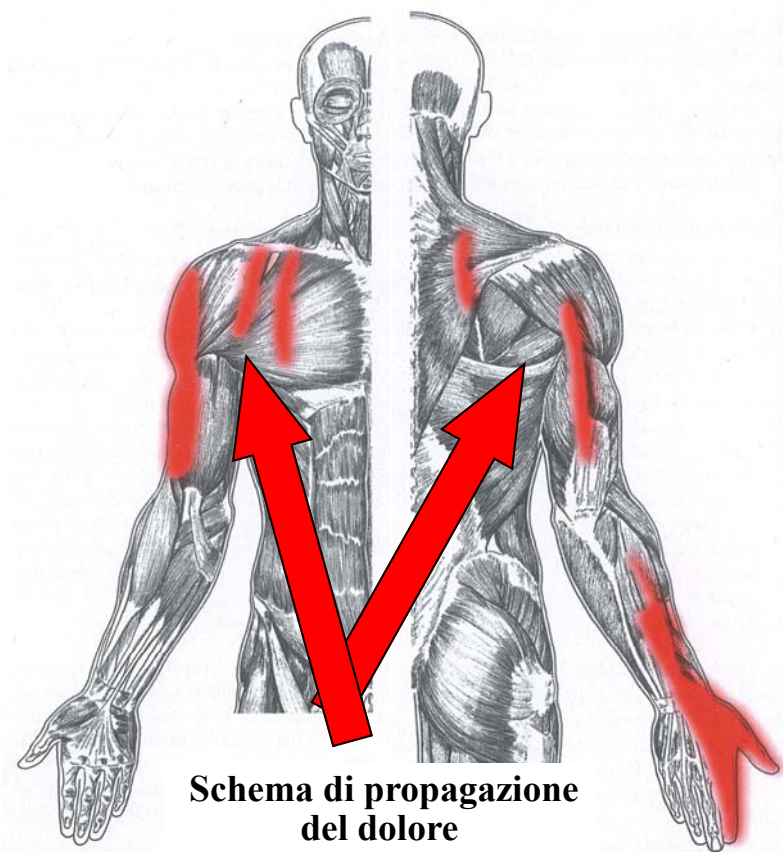
**Schema di propagazione del dolore**



## Scaleni

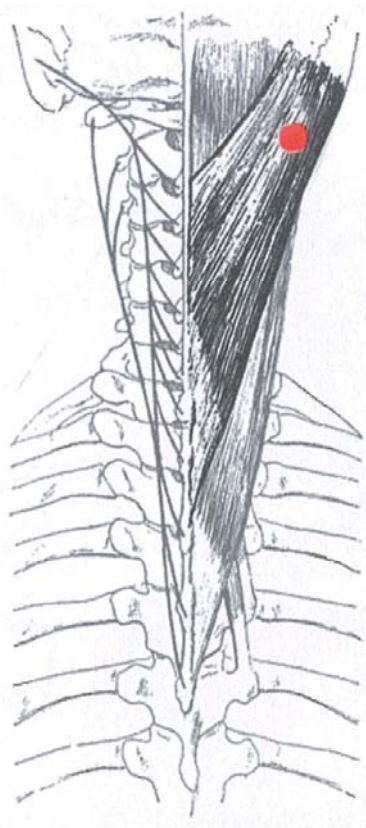


**Il tendine contratto**



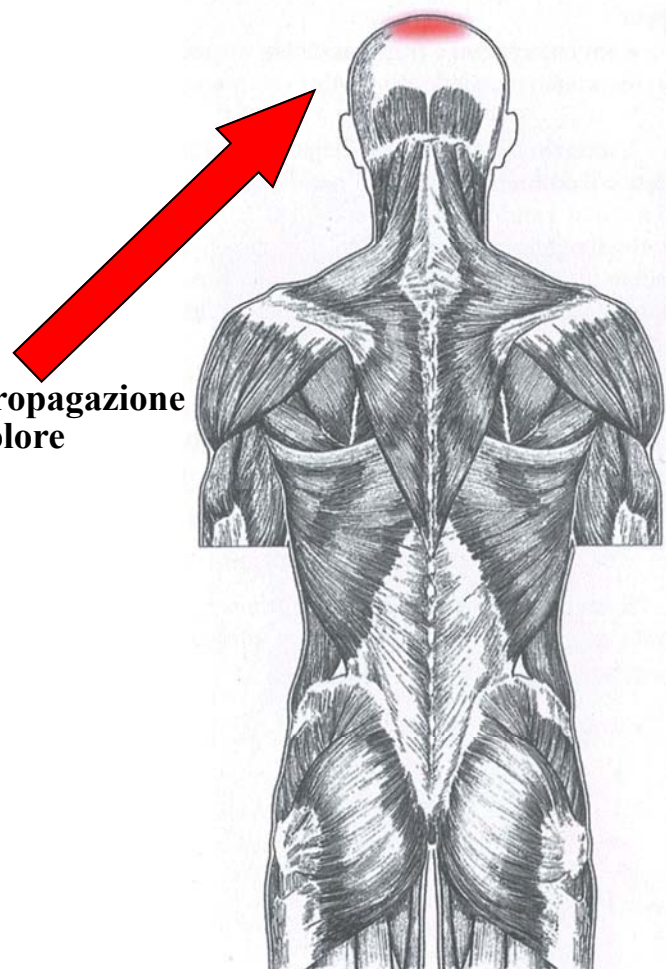
**Schema di propagazione del dolore**

## Splenio del corpo

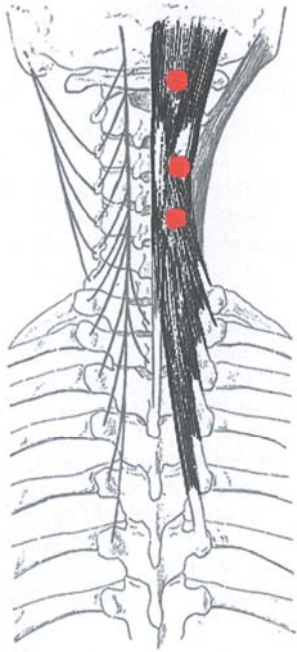


**Il tendine contratto**

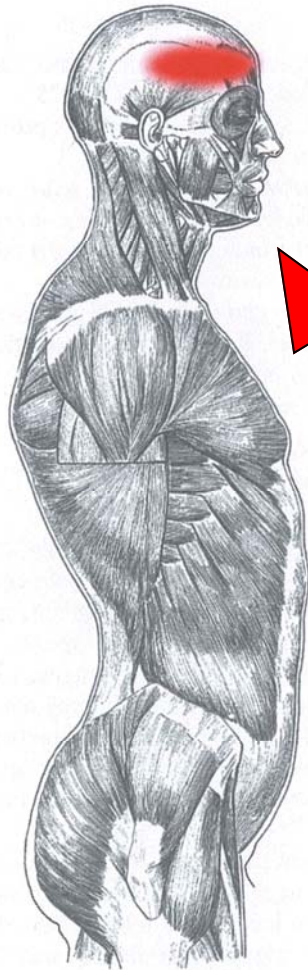
**Schema di propagazione del dolore**



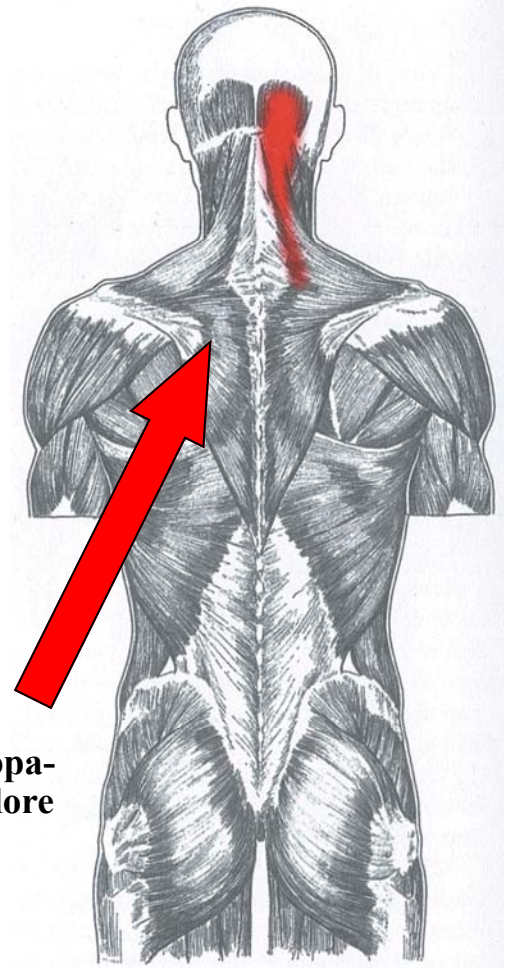
## Cervicali posteriore



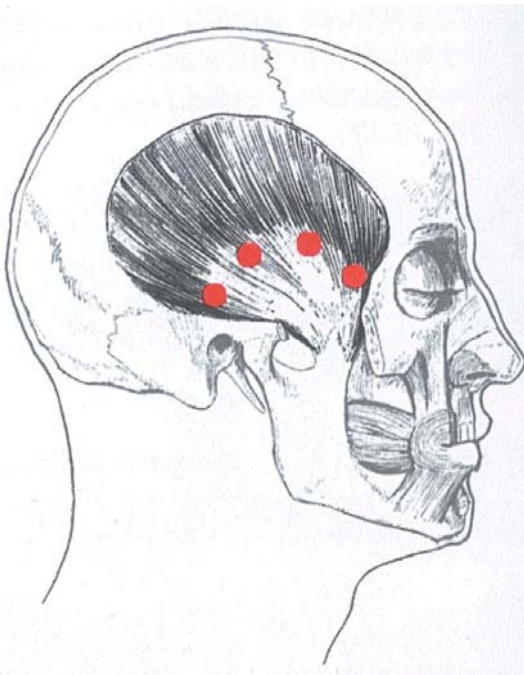
**Il tendine contratto**



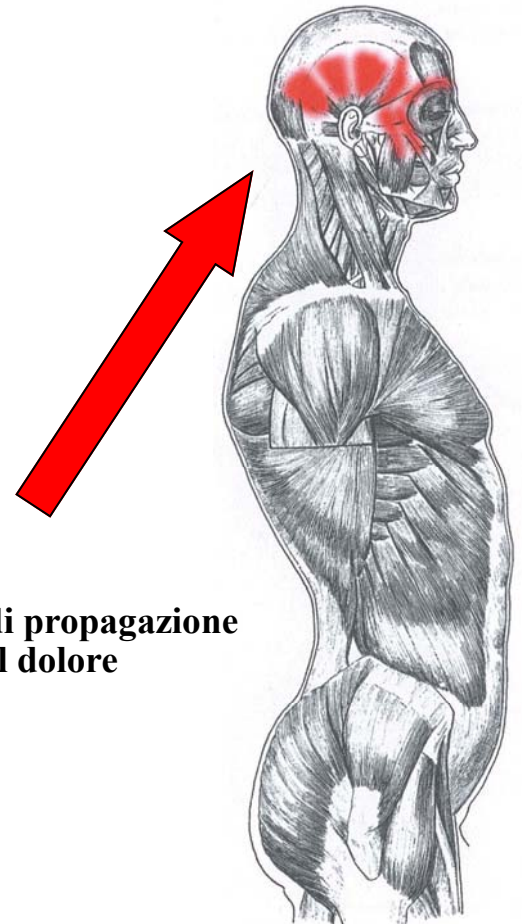
**Schema di propa-  
gazione del dolore**



## Temporale

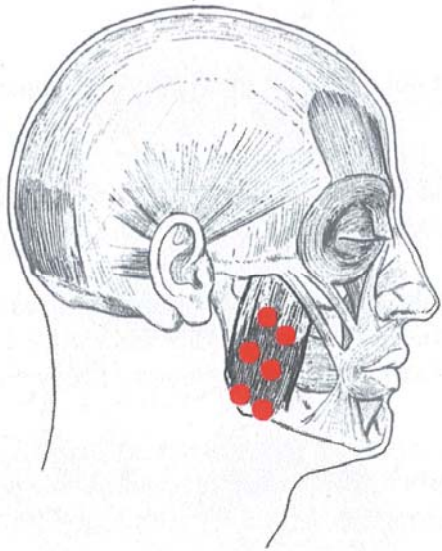


**Il tendine contratto**



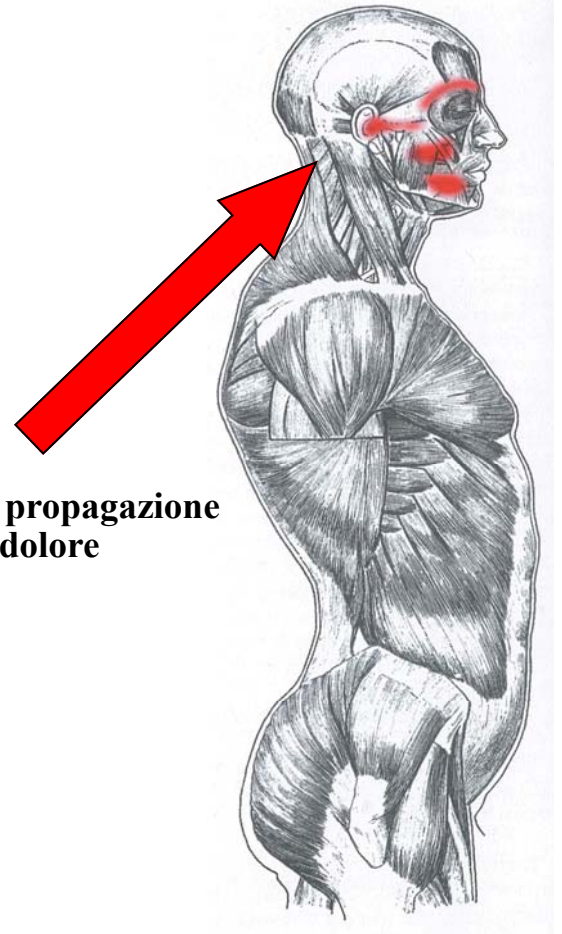
**Schema di propagazione  
del dolore**

## Massetere

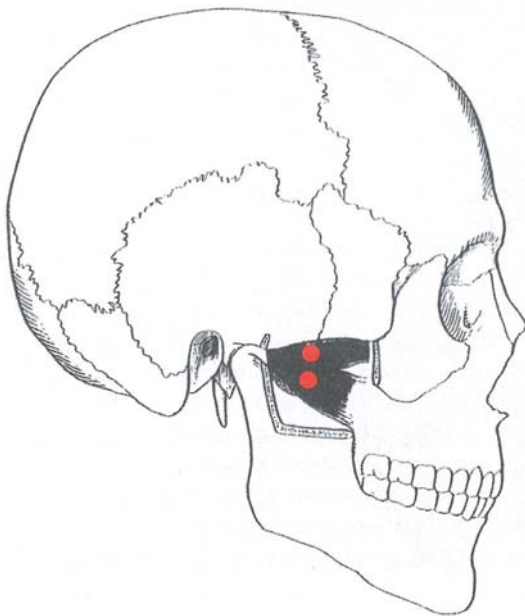


**Il tendine contratto**

**Schema di propagazione  
del dolore**

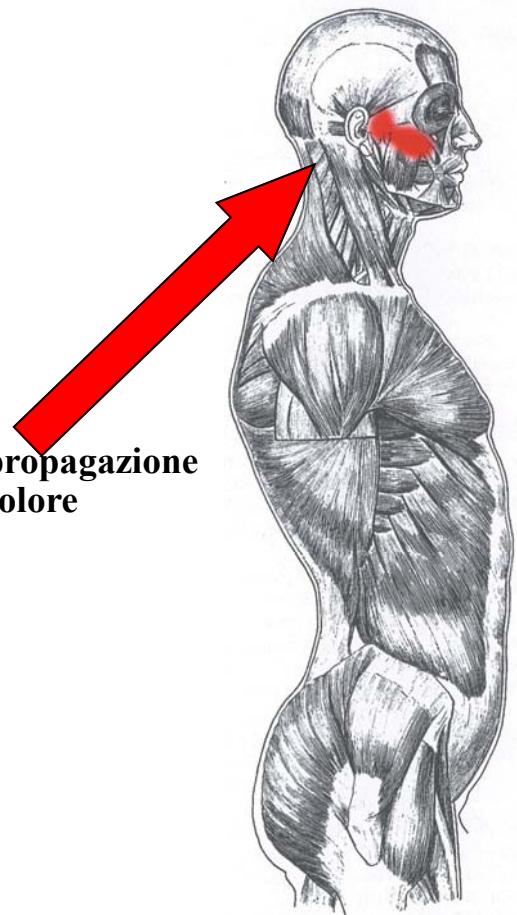


## Pterigoideo laterale

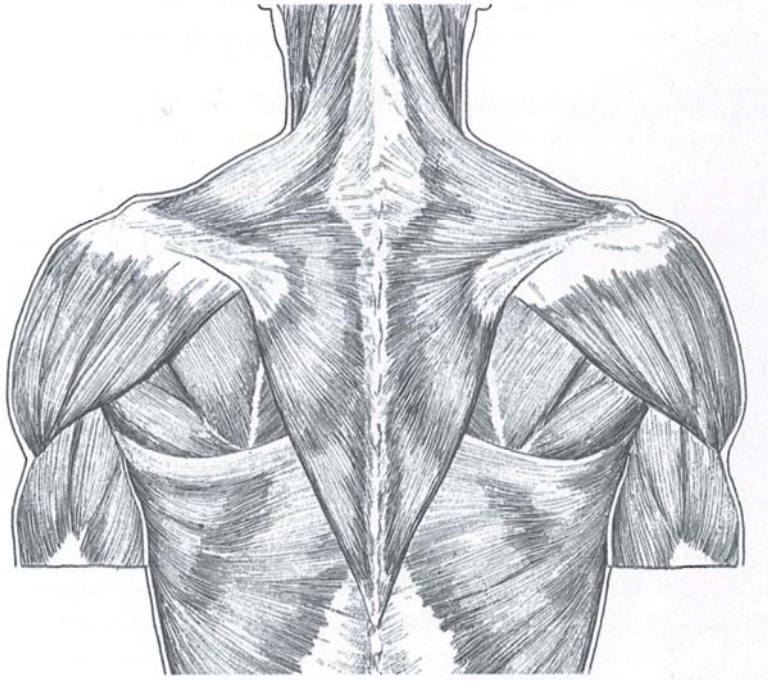


**Il tendine contratto**

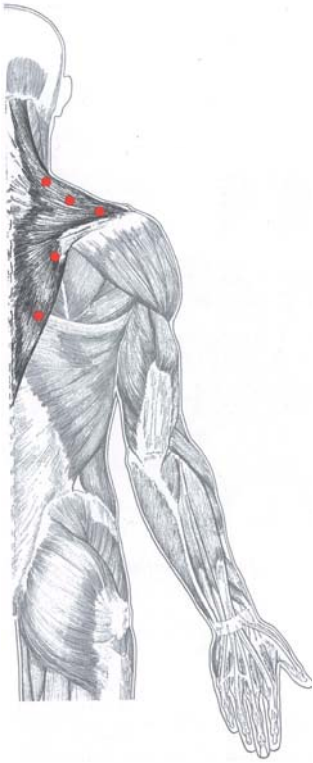
**Schema di propagazione  
del dolore**



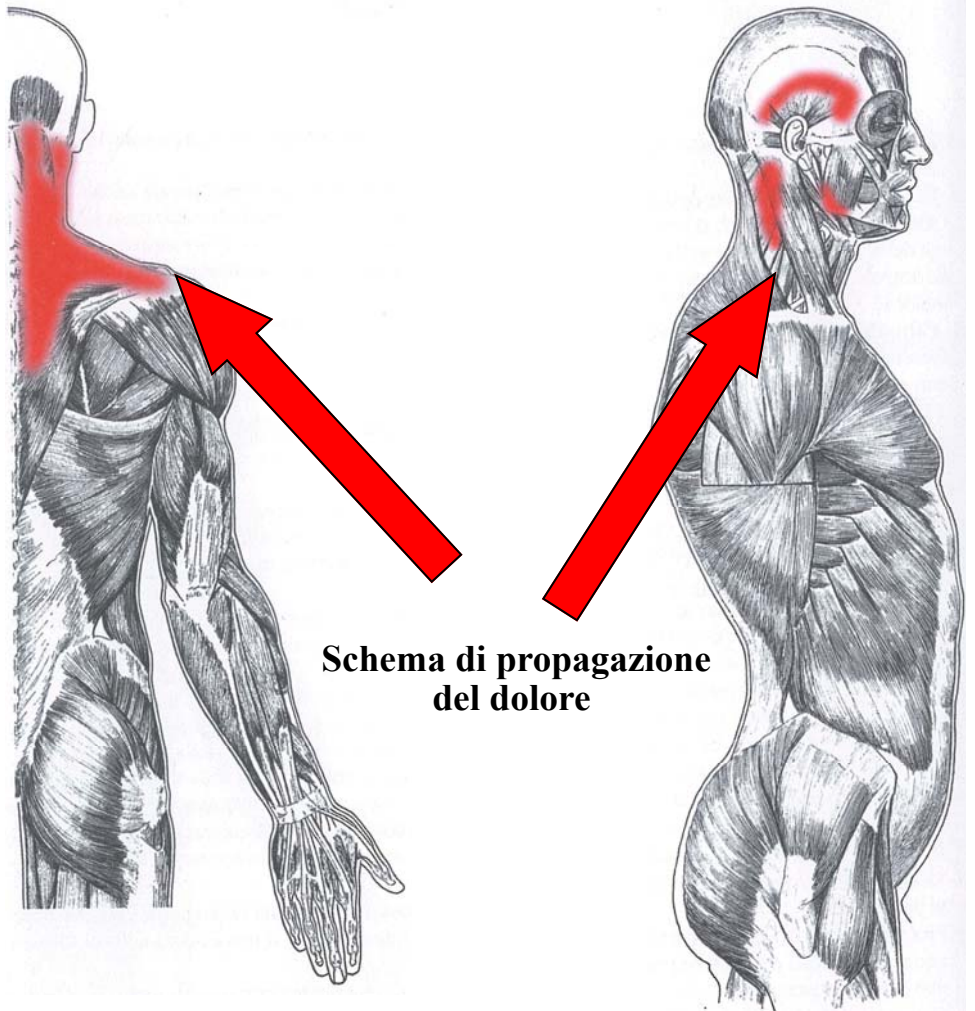
## Muscoli del cingolo scapolare



Trapezio

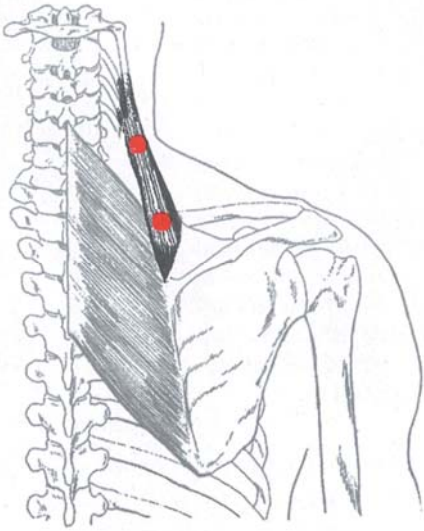


**Il tendine contratto**

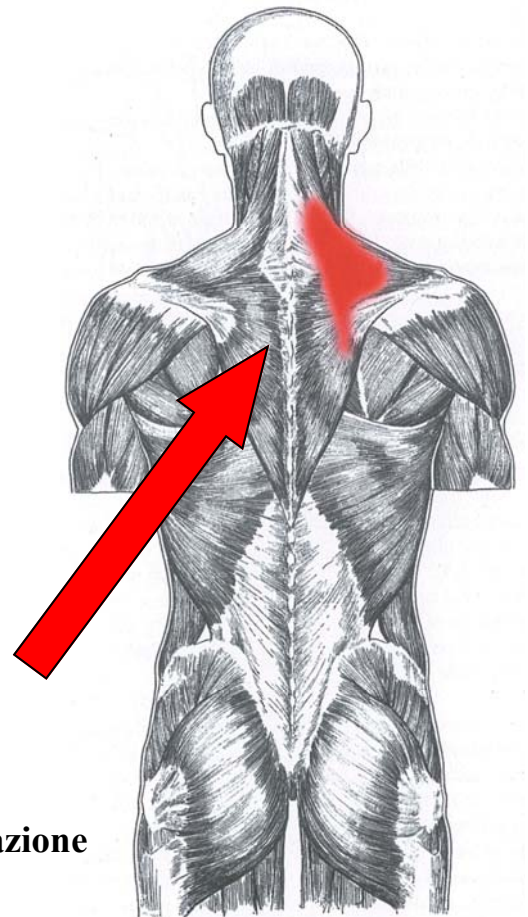


**Schema di propagazione del dolore**

## Elevatore delle scapole

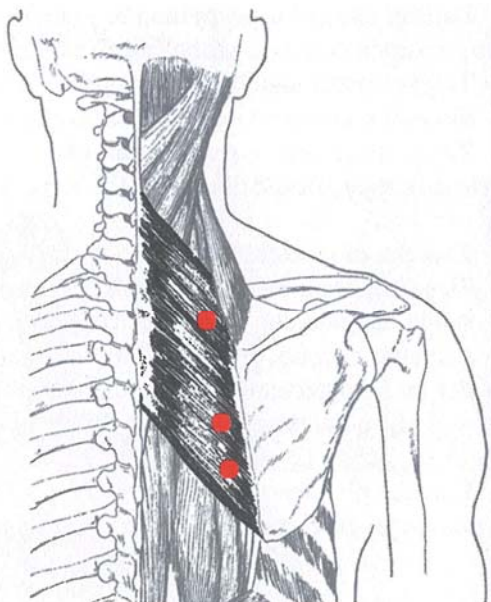


**Il tendine contratto**

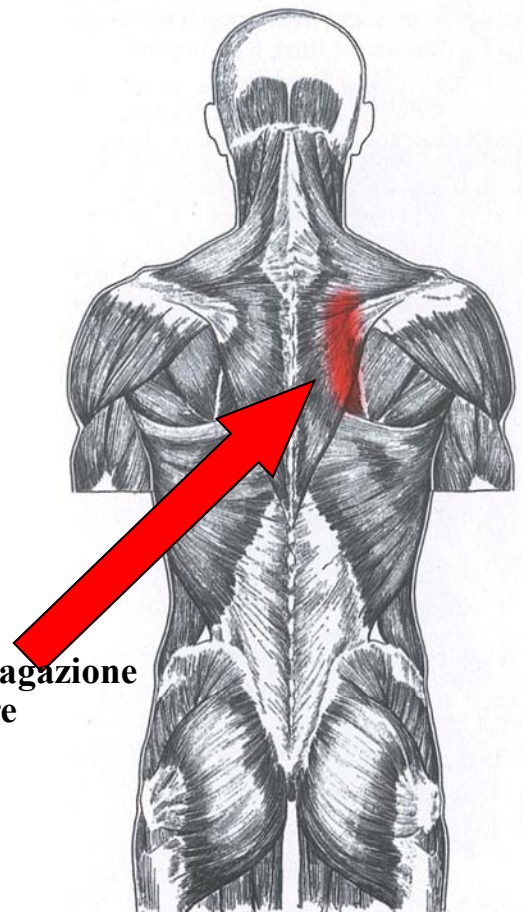


**Schema di propagazione  
del dolore**

## Romboidei

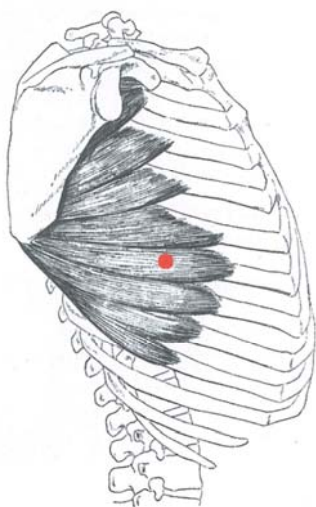


**Il tendine contratto**

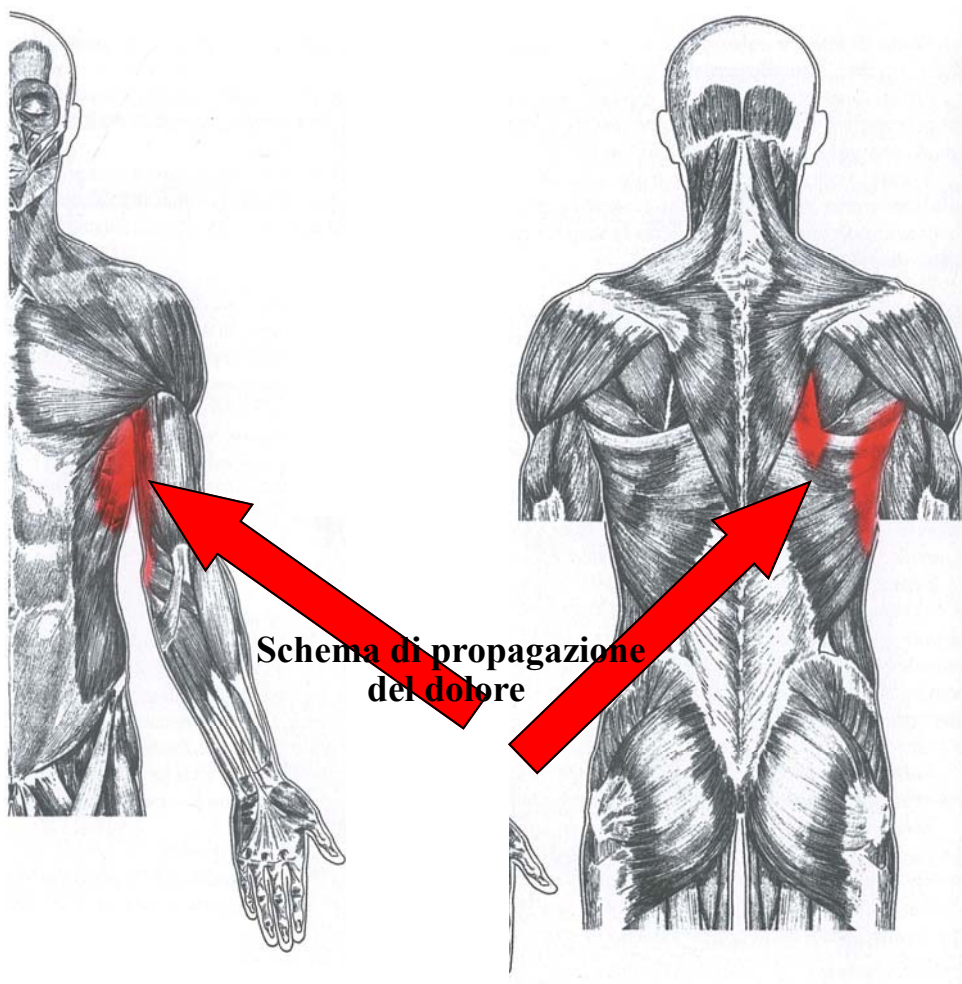


**Schema di propagazione  
del dolore**

## Serrato anteriore

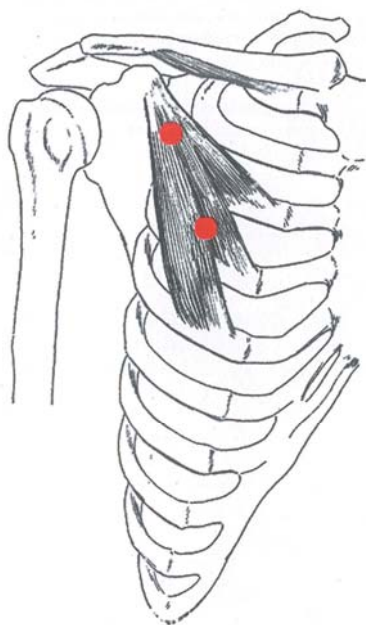


**Il tendine contratto**

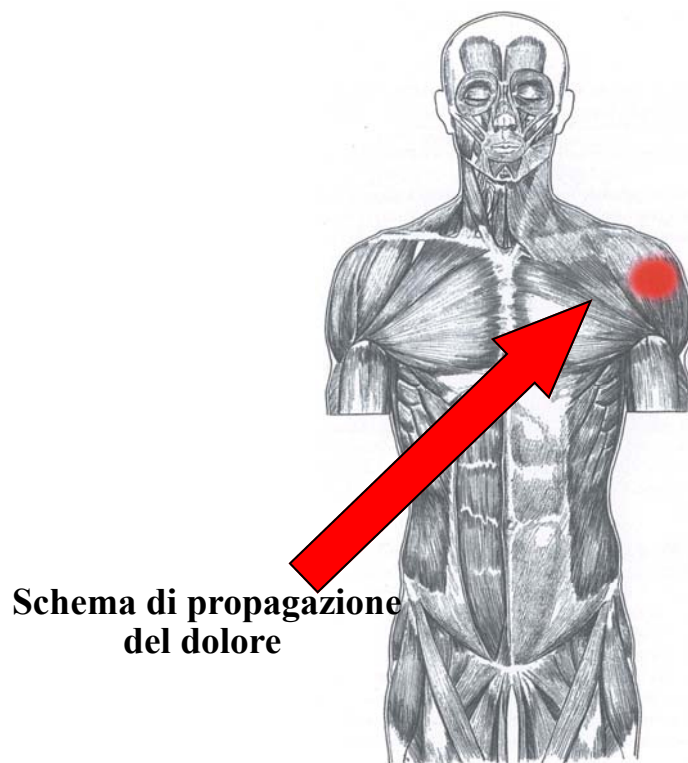


**Schema di propagazione  
del dolore**

## Piccolo pettorale



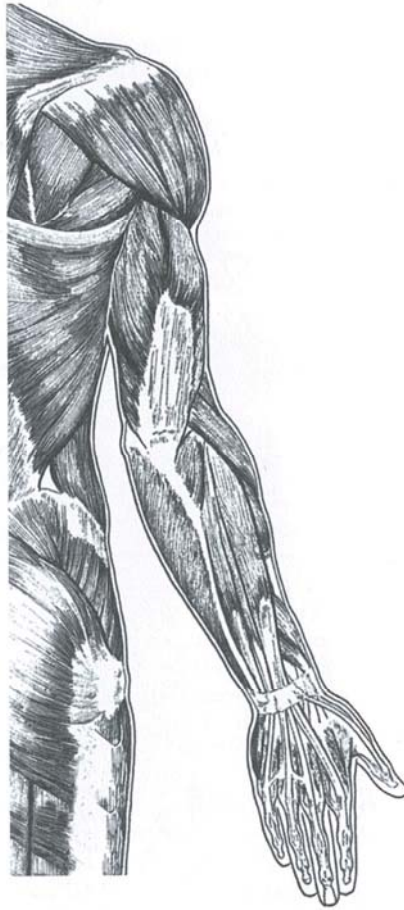
**Il tendine contratto**



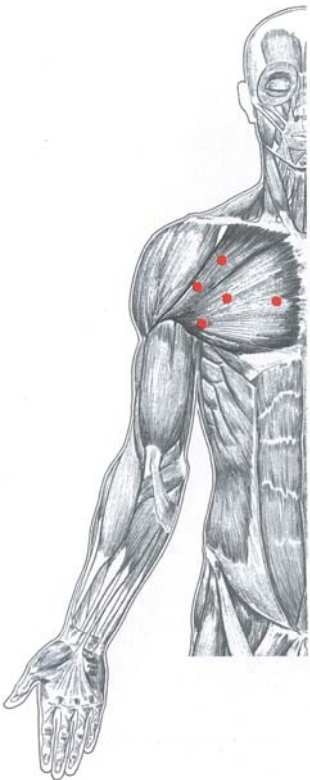
**Schema di propagazione  
del dolore**



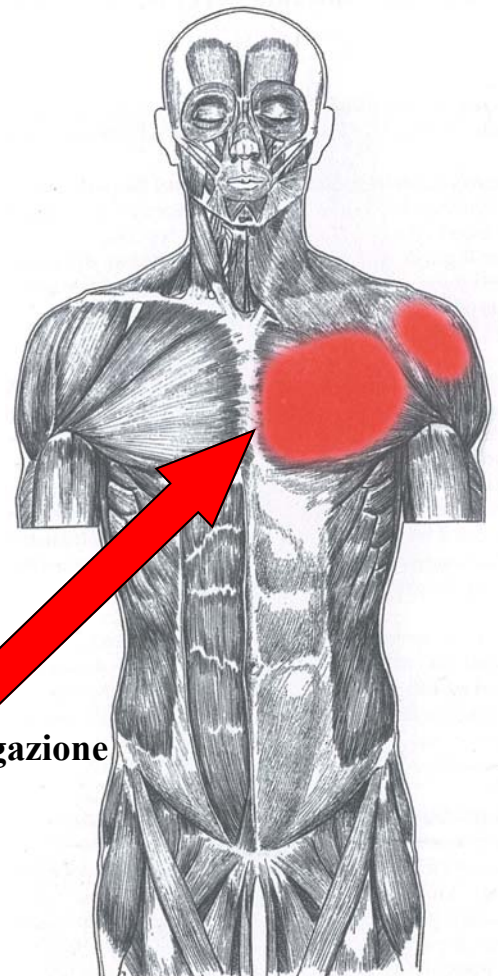
## Muscoli delle braccia



## Grande pettorale

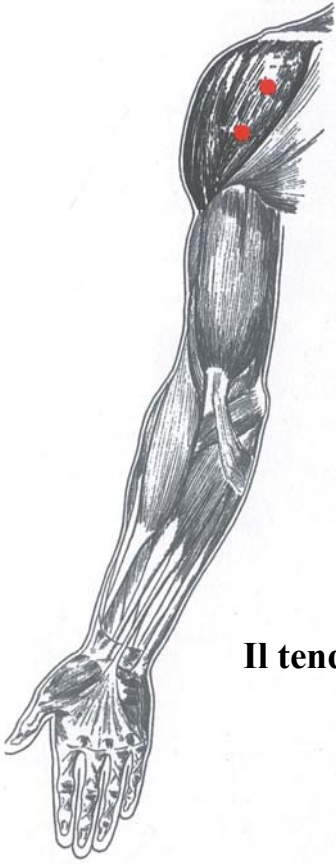

**Il tendine contratto**

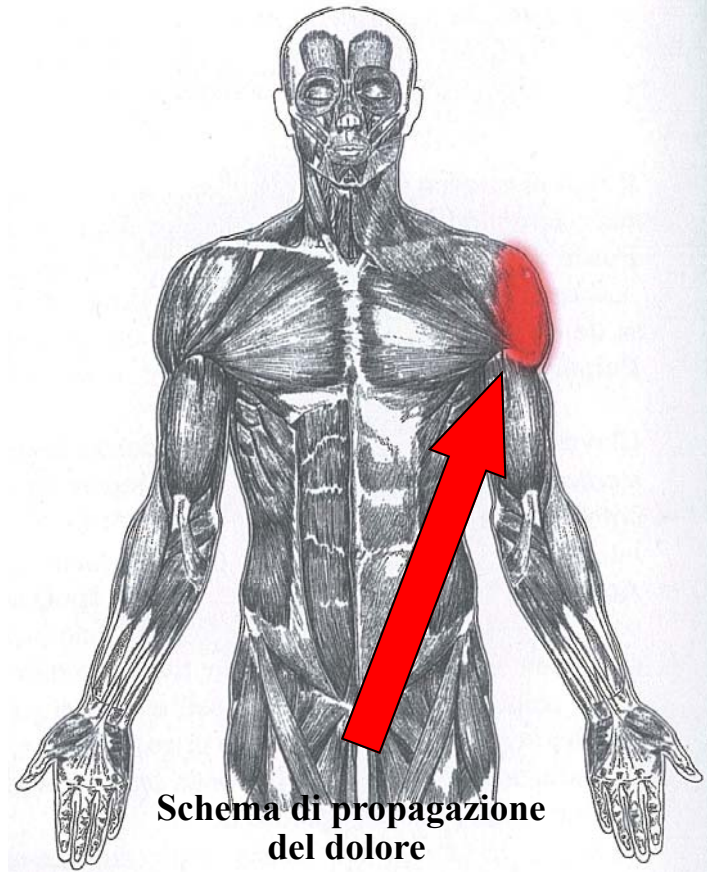


**Schema di propagazione  
del dolore**

## Deltoide anteriore

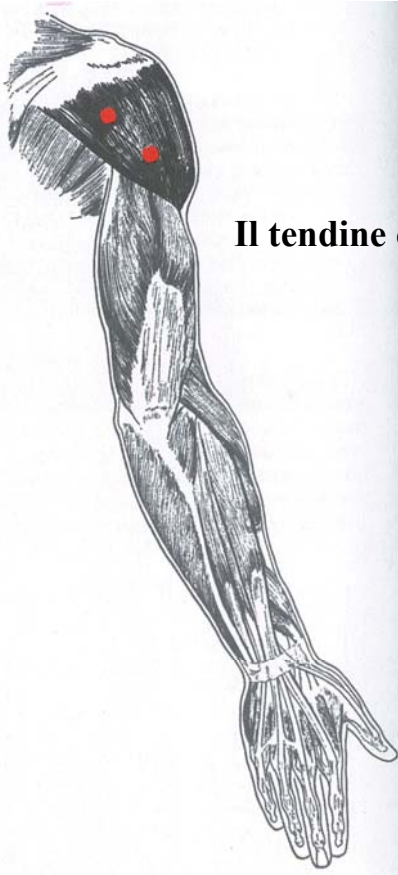


**Il tendine contratto**

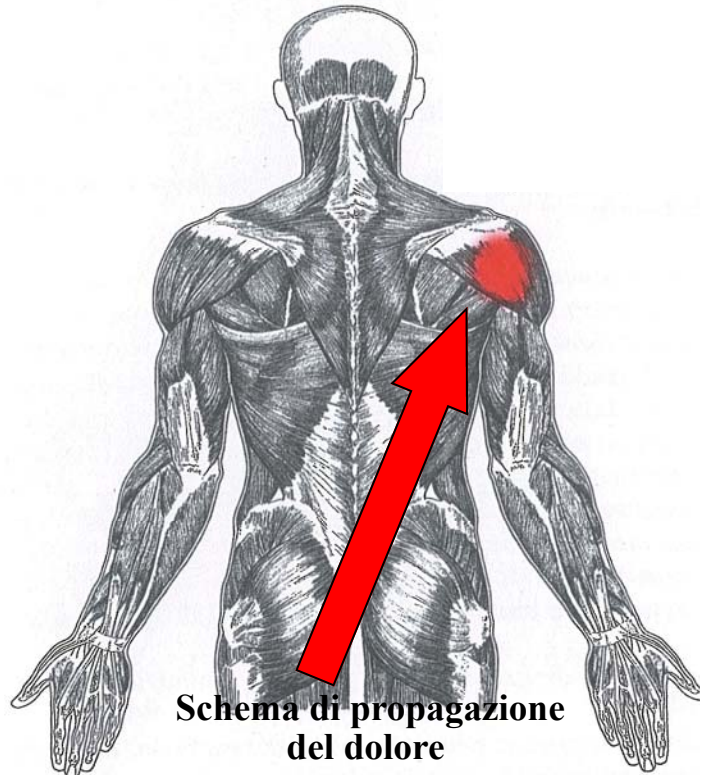


**Schema di propagazione del dolore**

## Deltoide posteriore

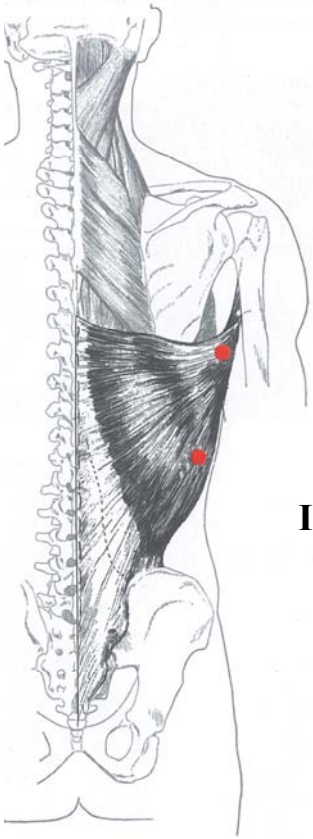


**Il tendine contratto**

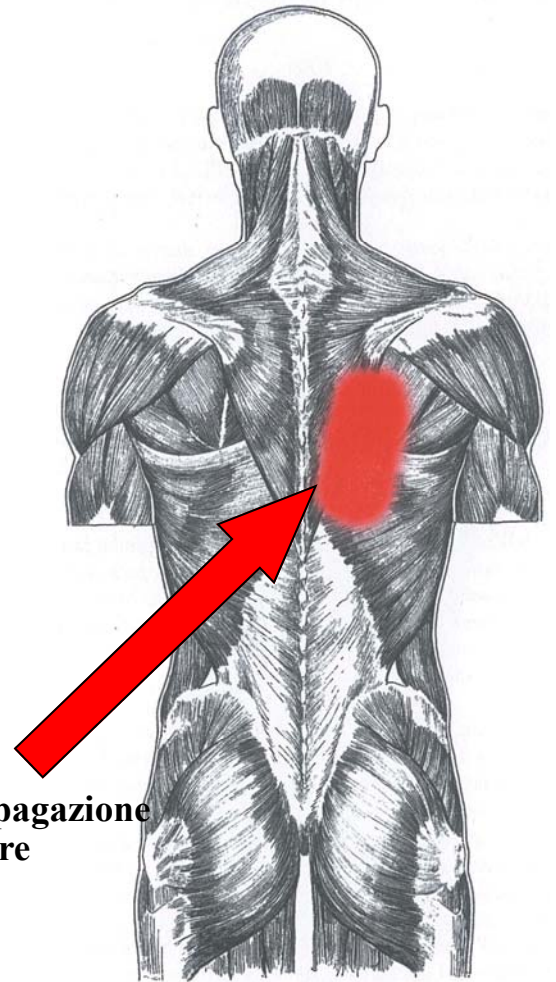


**Schema di propagazione del dolore**

## Grande dorsale

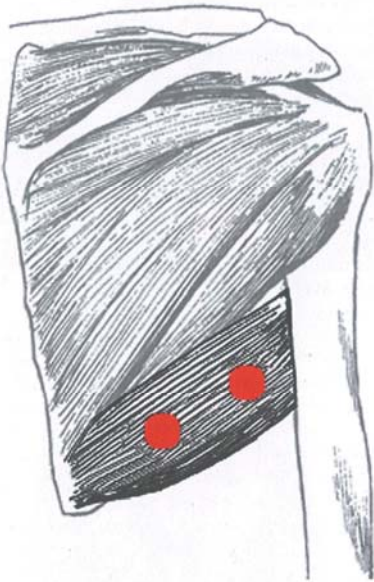


**Il tendine contratto**

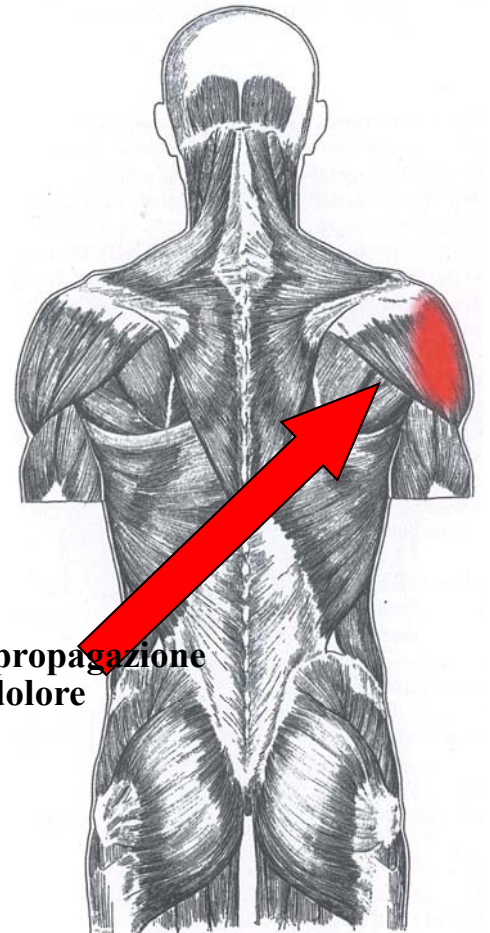


**Schema di propagazione  
del dolore**

## Grande rotondo



**Il tendine contratto**

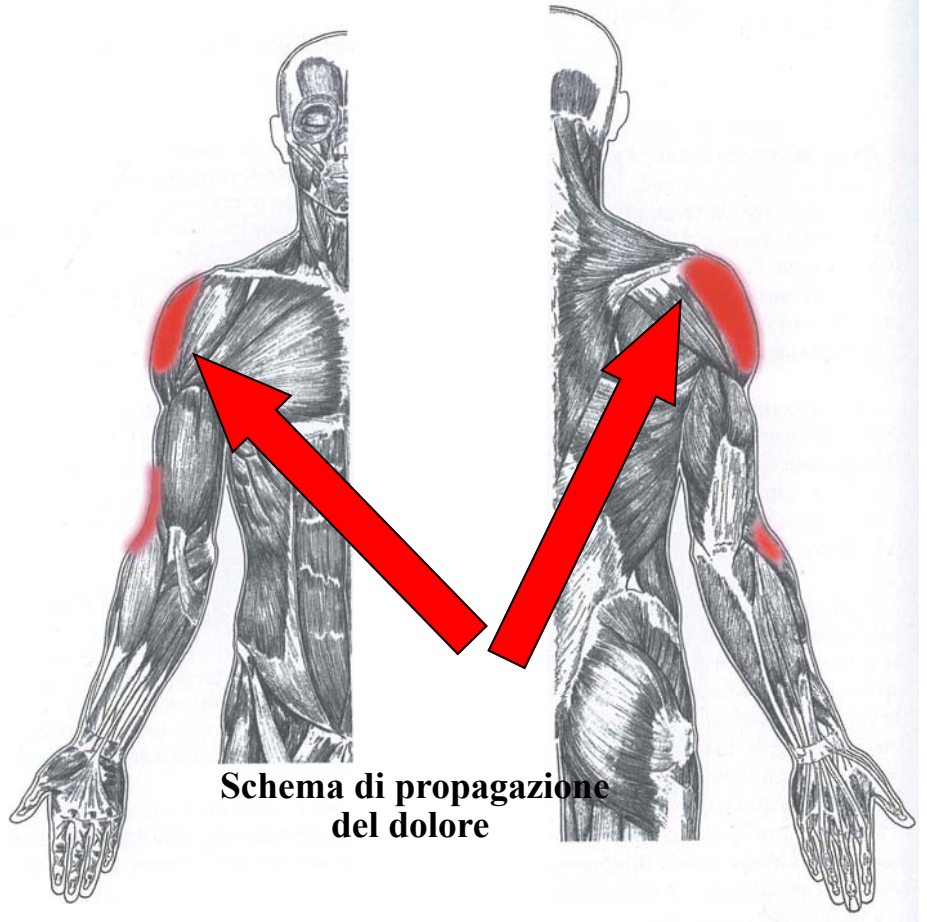


**Schema di propagazione  
del dolore**

**sovra spinato**

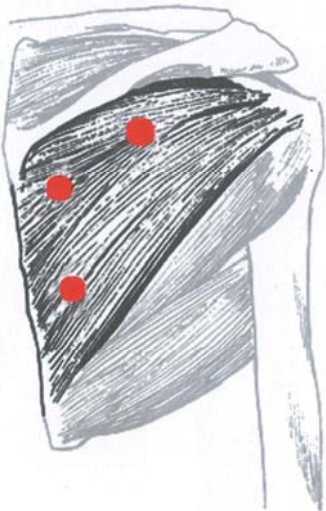


**Il tendine contratto**

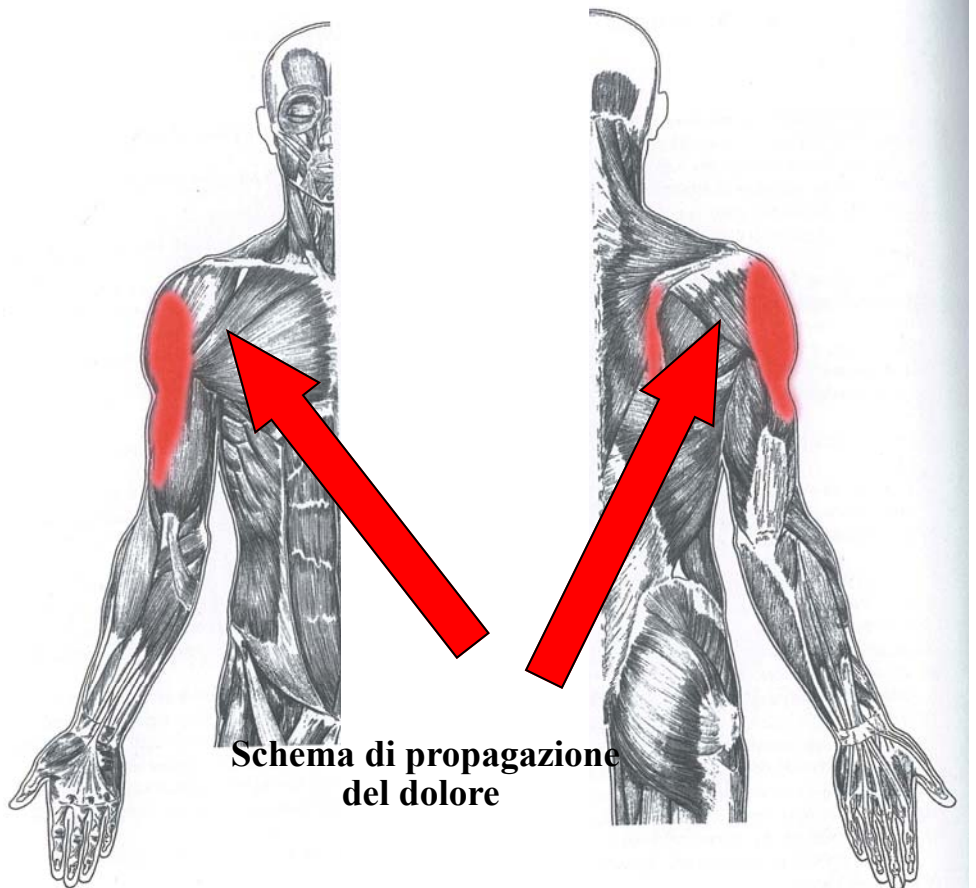


**Schema di propagazione del dolore**

**Infraspinato**

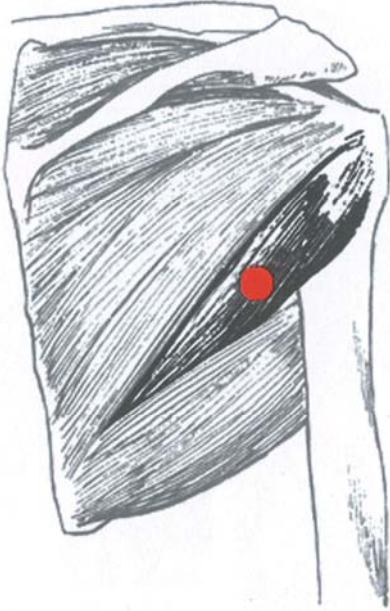


**Il tendine contratto**

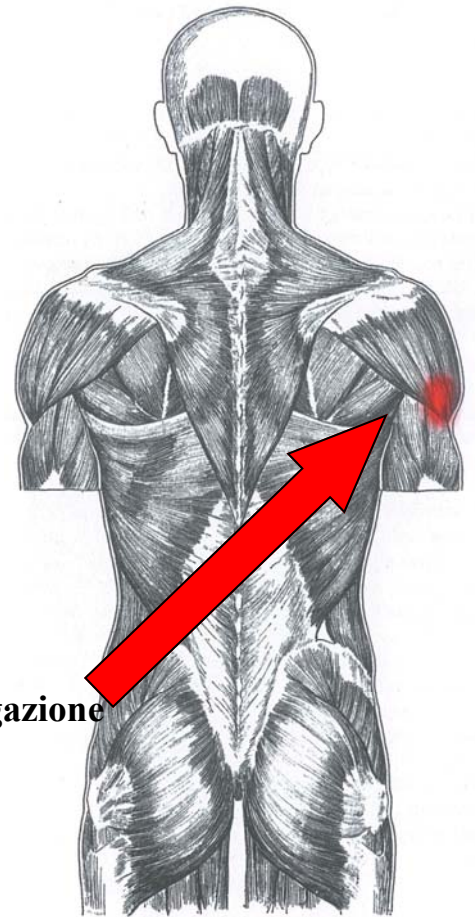


**Schema di propagazione del dolore**

**Piccolo rotondo**

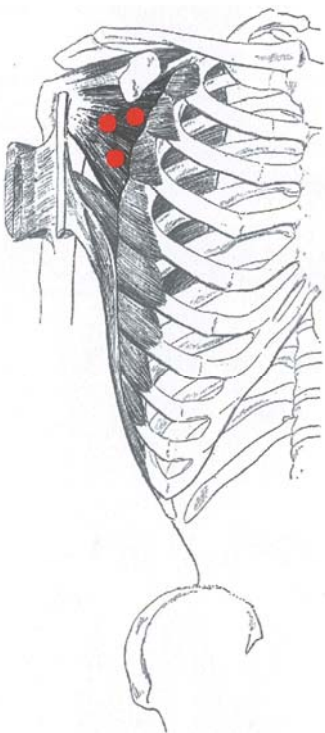


**Il tendine contratto**

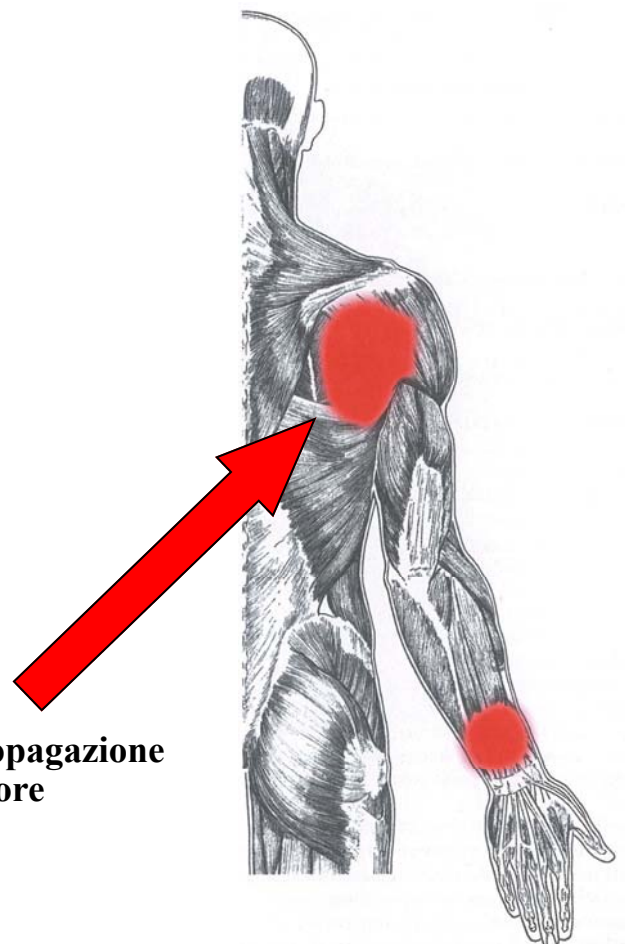


**Schema di propagazione del dolore**

**sottoscapolare**

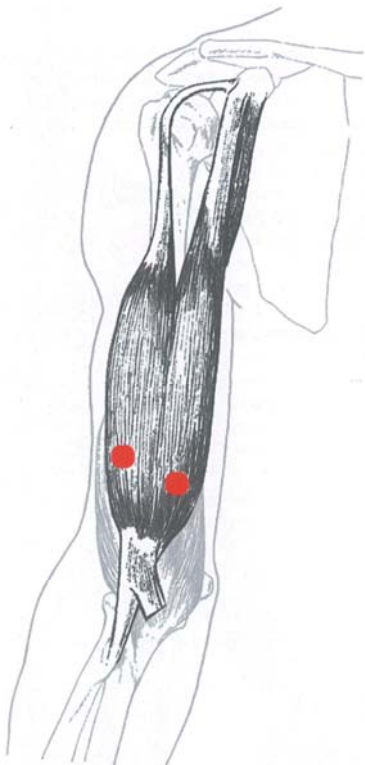


**Il tendine contratto**



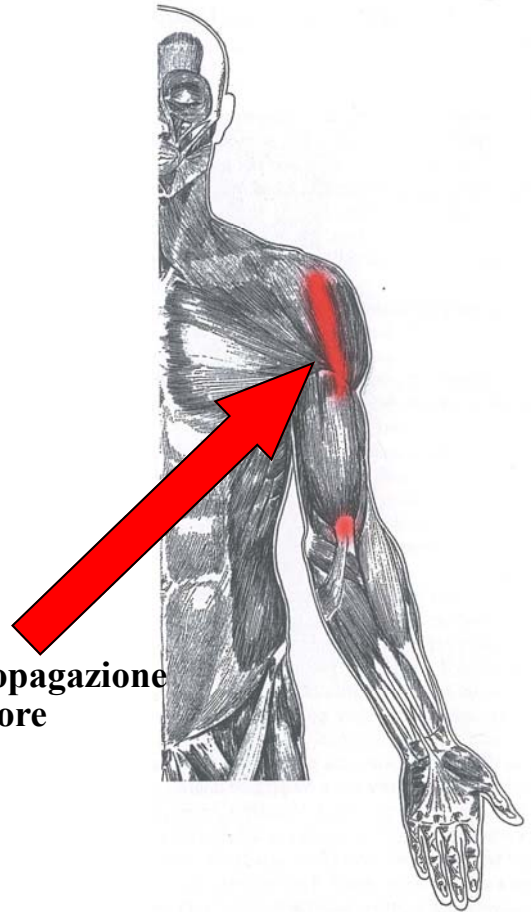
**Schema di propagazione del dolore**

## Bicipite branchiale

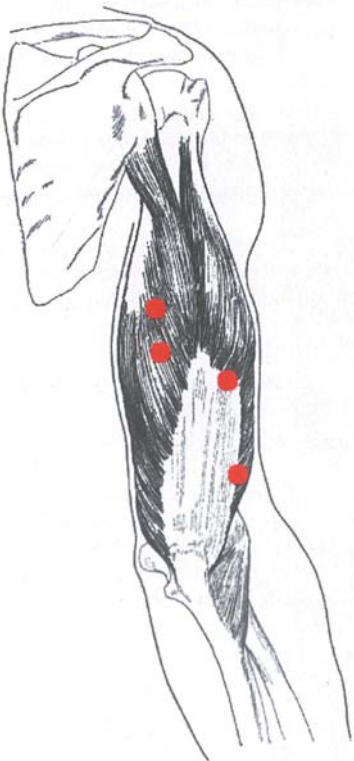


**Il tendine contratto**

**Schema di propagazione  
del dolore**

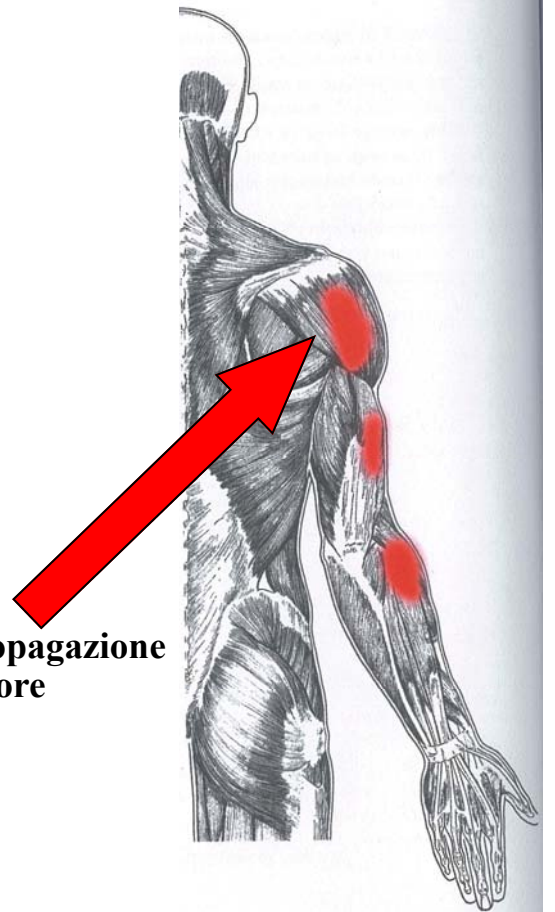


## Tricipite brachiale

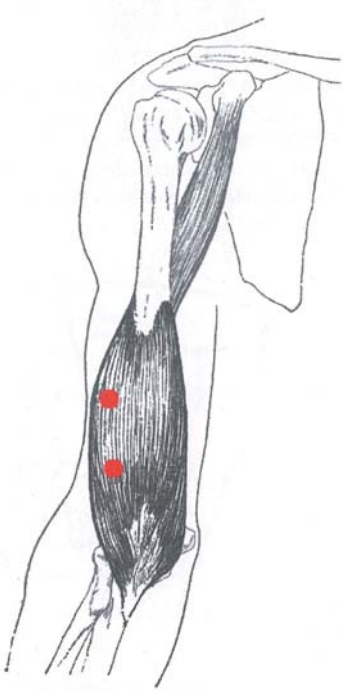


**Il tendine contratto**

**Schema di propagazione  
del dolore**

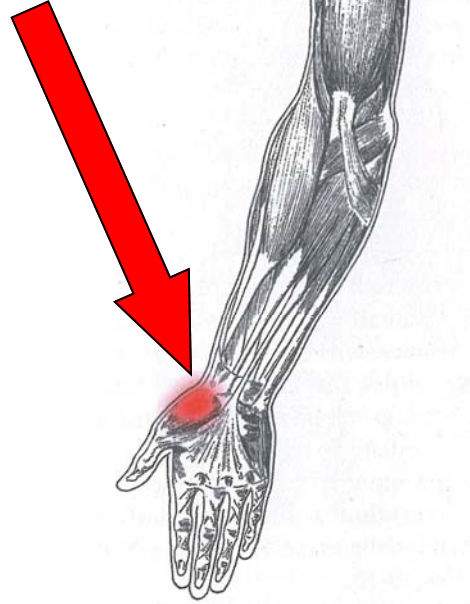


## Branchiale

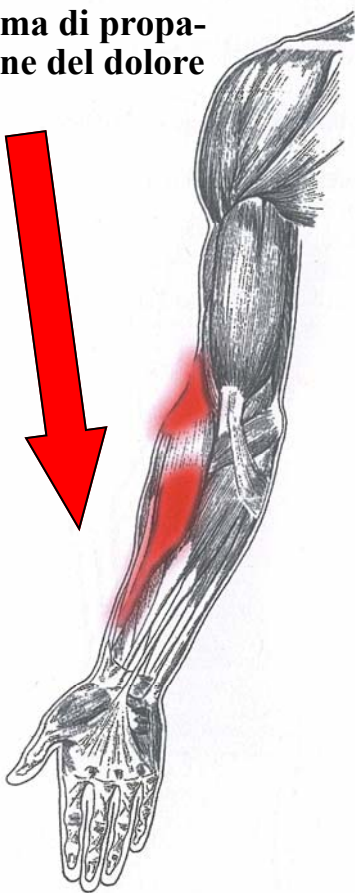

Il tendine contratto

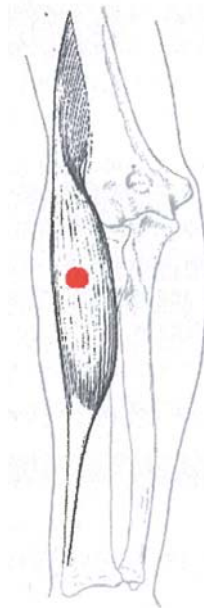
Schema di propagazione del dolore



Schema di propagazione del dolore

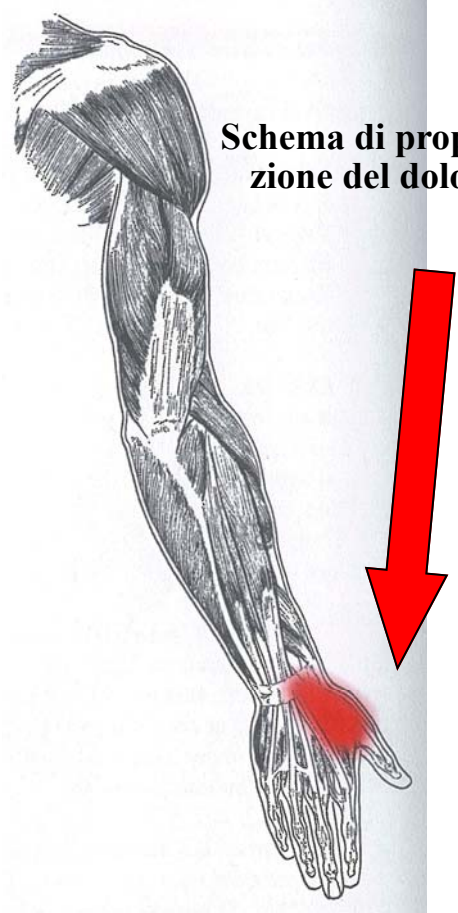


## Brachioradiale

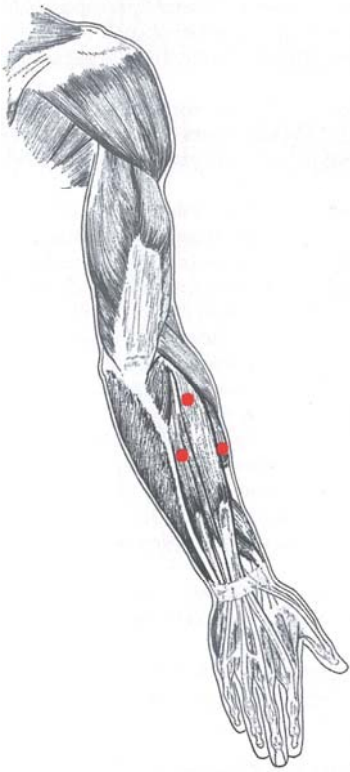


Il tendine contratto

Schema di propagazione del dolore

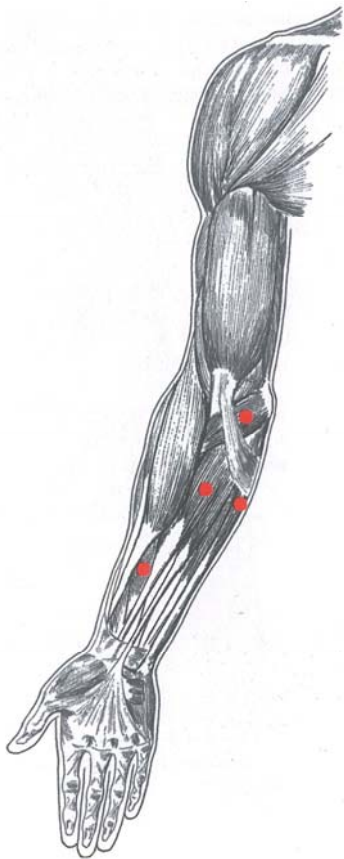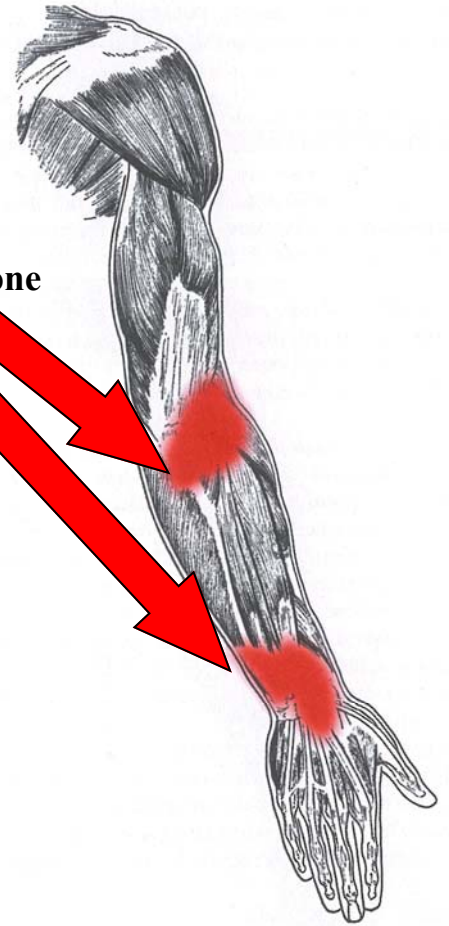


**Estensori della mano**



**Il tendine contratto**

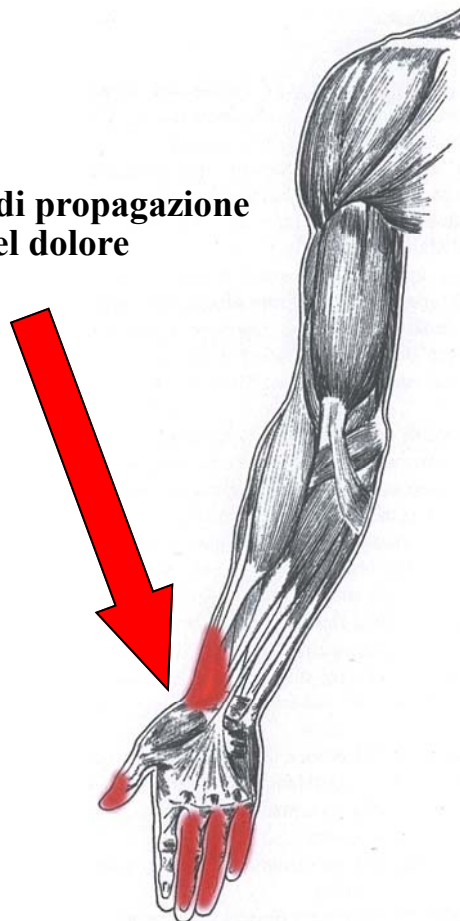
**Schema di propagazione  
del dolore**



**Il tendine contratto**

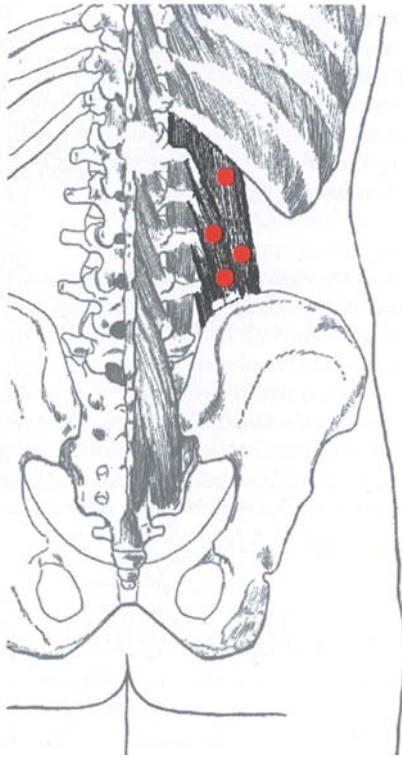
**Flessori della mano**

**Schema di propagazione  
del dolore**

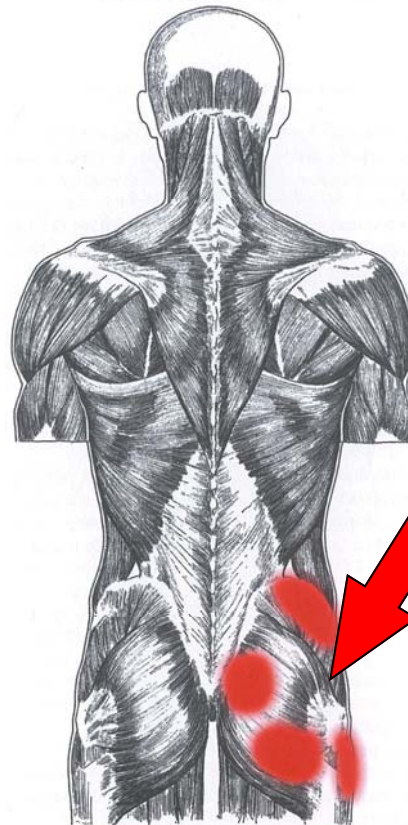




## Quadrato dei lombi

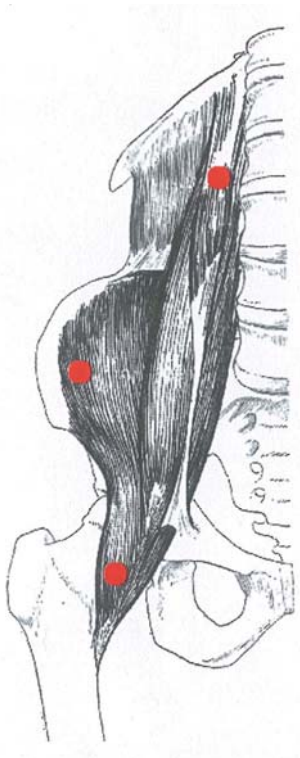


**Il tendine contratto**



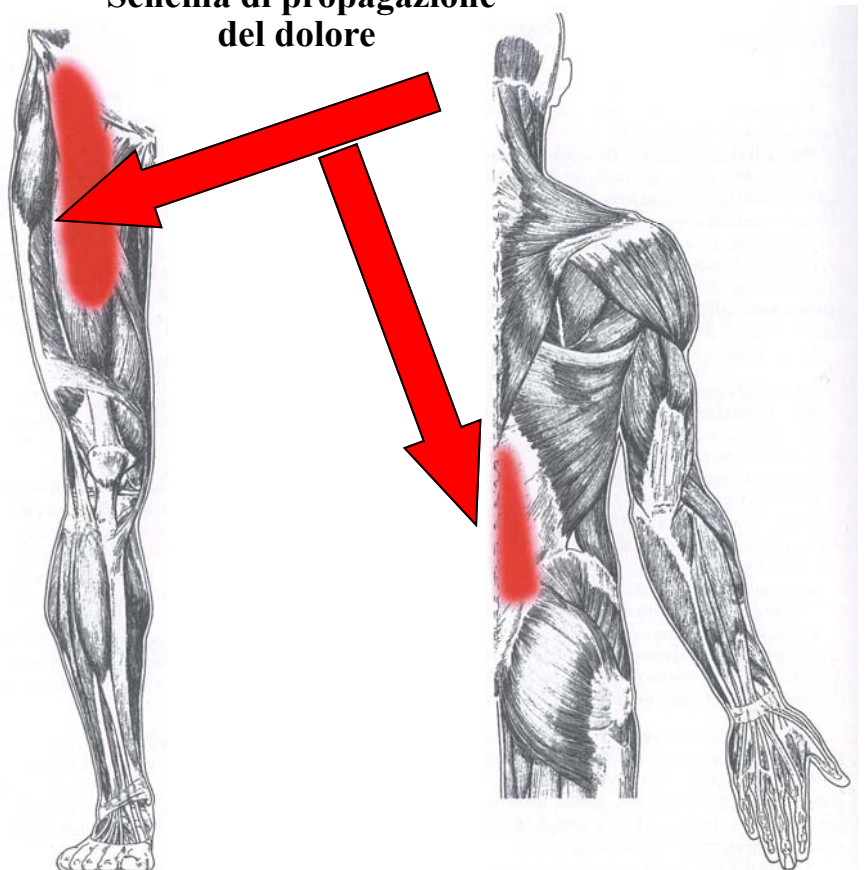
**Schema di propagazione del dolore**

## Ileopsoas



**Il tendine contratto**

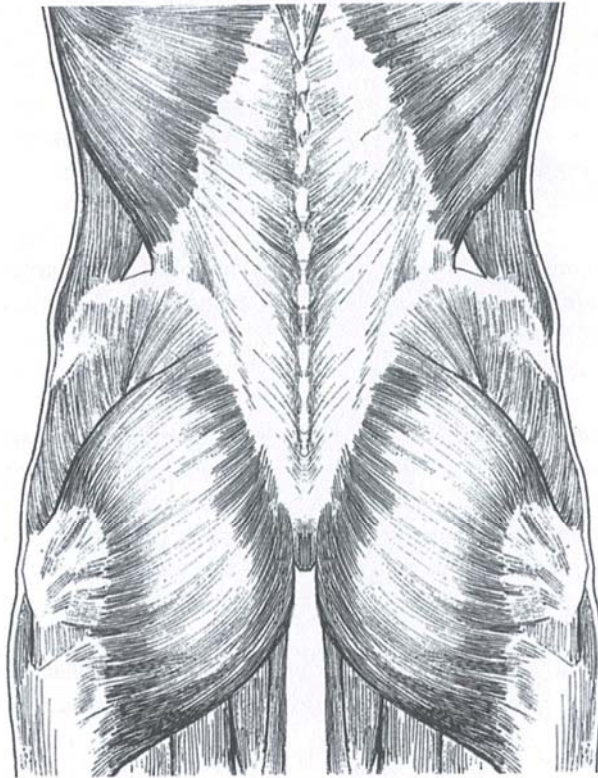
**Schema di propagazione del dolore**



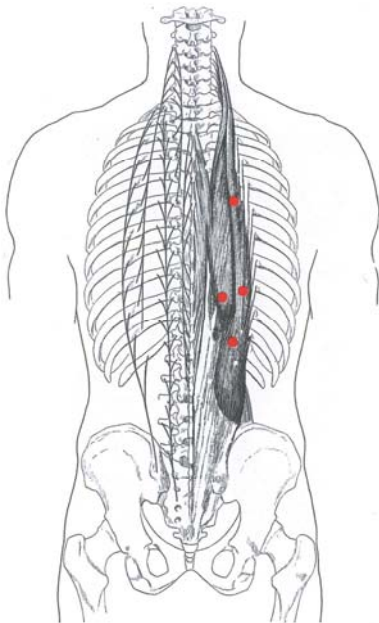
**Ileopsoas anteriore**

**Ileopsoas posteriore**

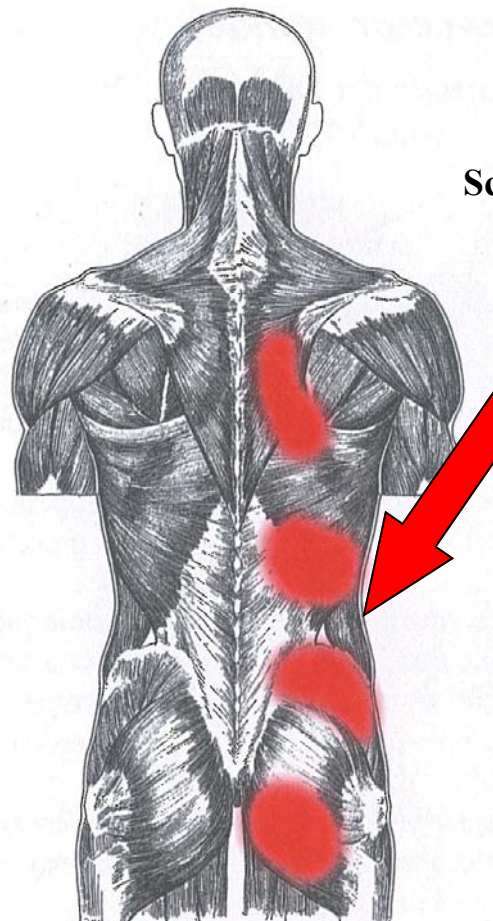
## Muscoli del torace



## Erettori della colonna

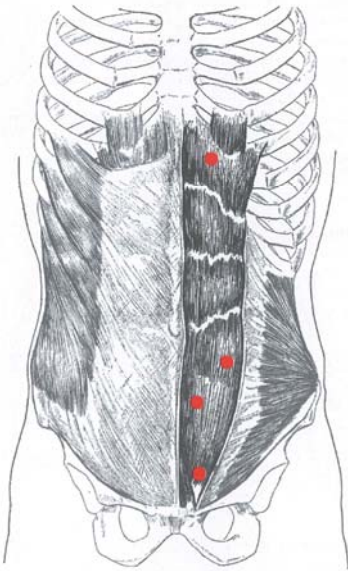


**Il tendine contratto**



**Schema di propagazione  
del dolore**

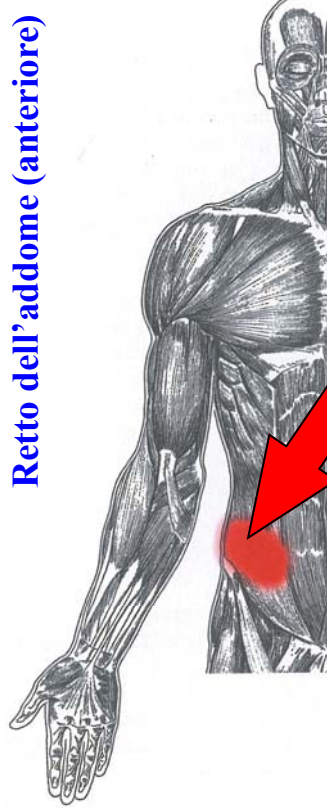
**Retto dell'addome**



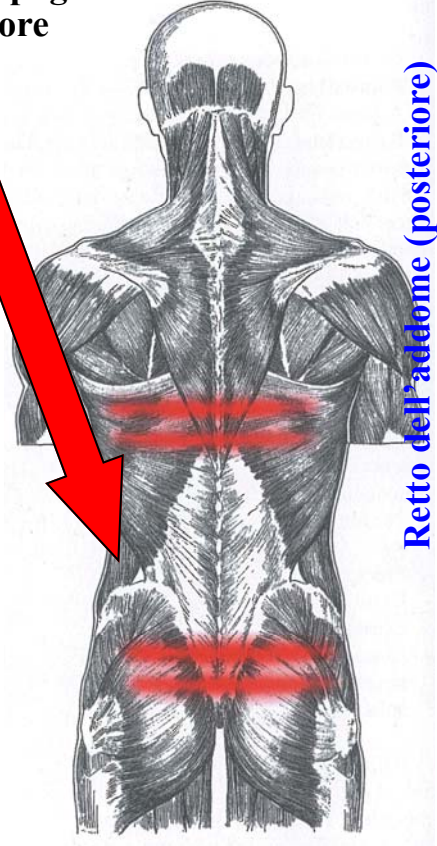
**Il tendine contratto**

**Schema di propagazione del dolore**

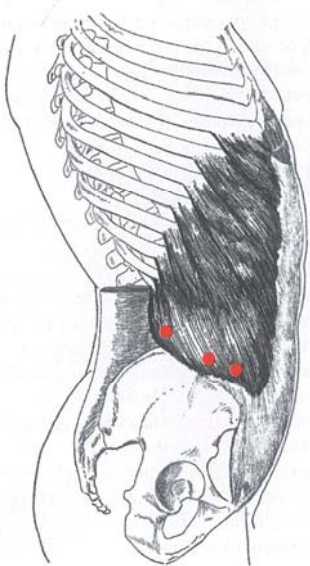
**Retto dell'addome (anteriore)**



**Retto dell'addome (posteriore)**

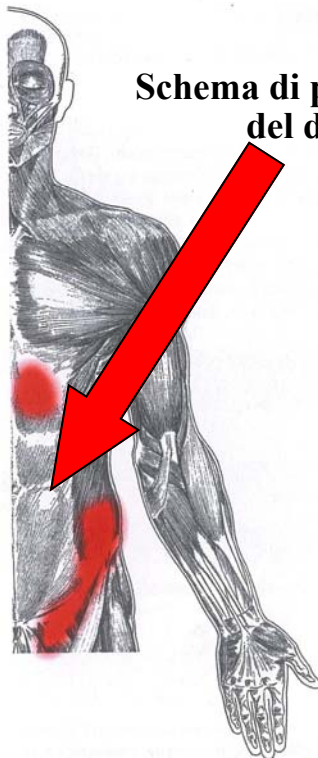


**Addominali (obliquo esterno)**

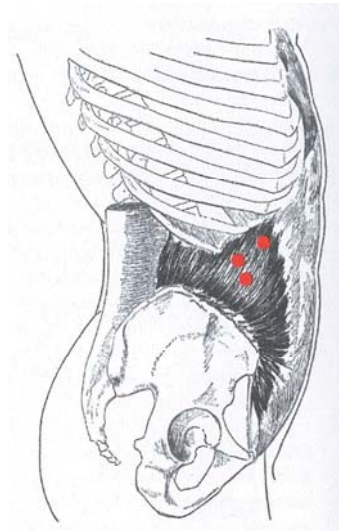


**Il tendine contratto**

**Schema di propagazione del dolore**

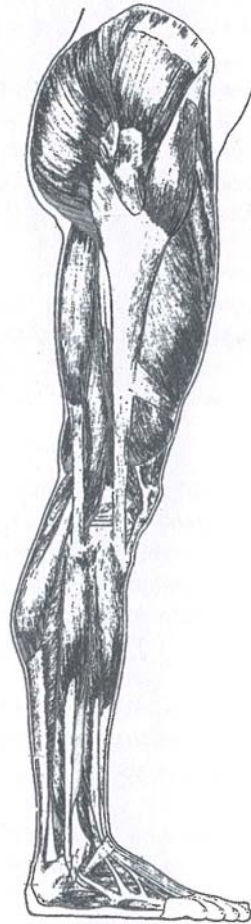

**Addominali (obliquo Interno)**

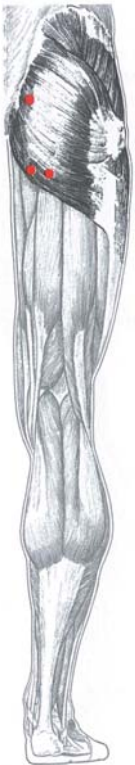

**Il tendine contratto**

## Muscoli delle gambe

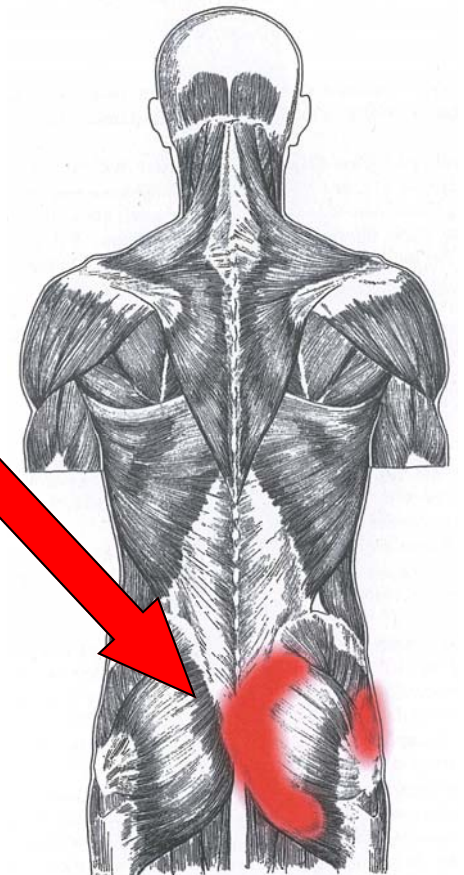


## Grande gluteo

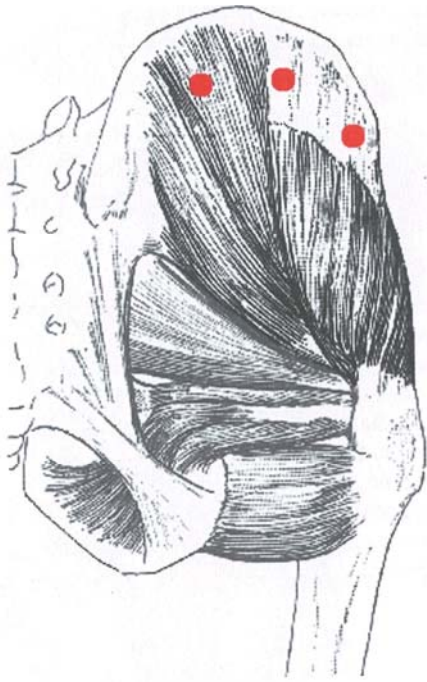


**Il tendine contratto**

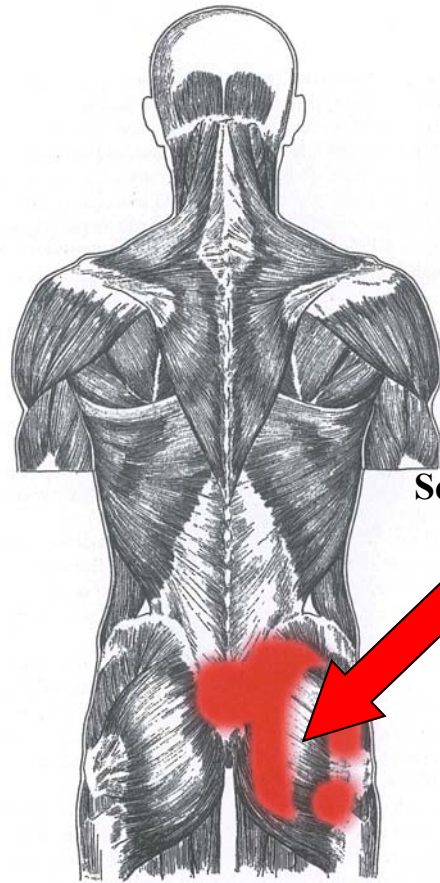
**Schema di propagazione  
del dolore**



Medio gluteo

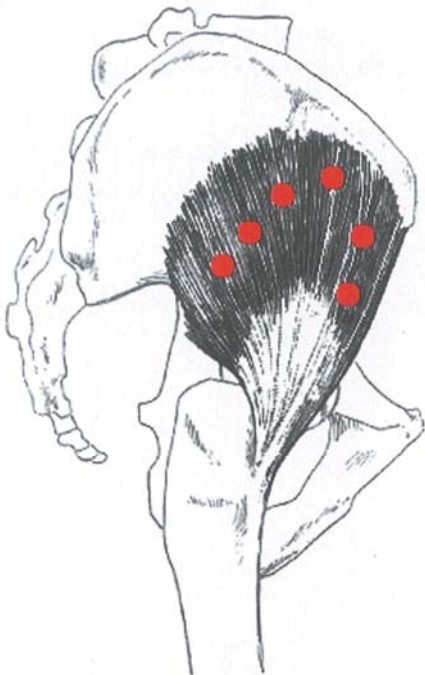


**Il tendine contratto**

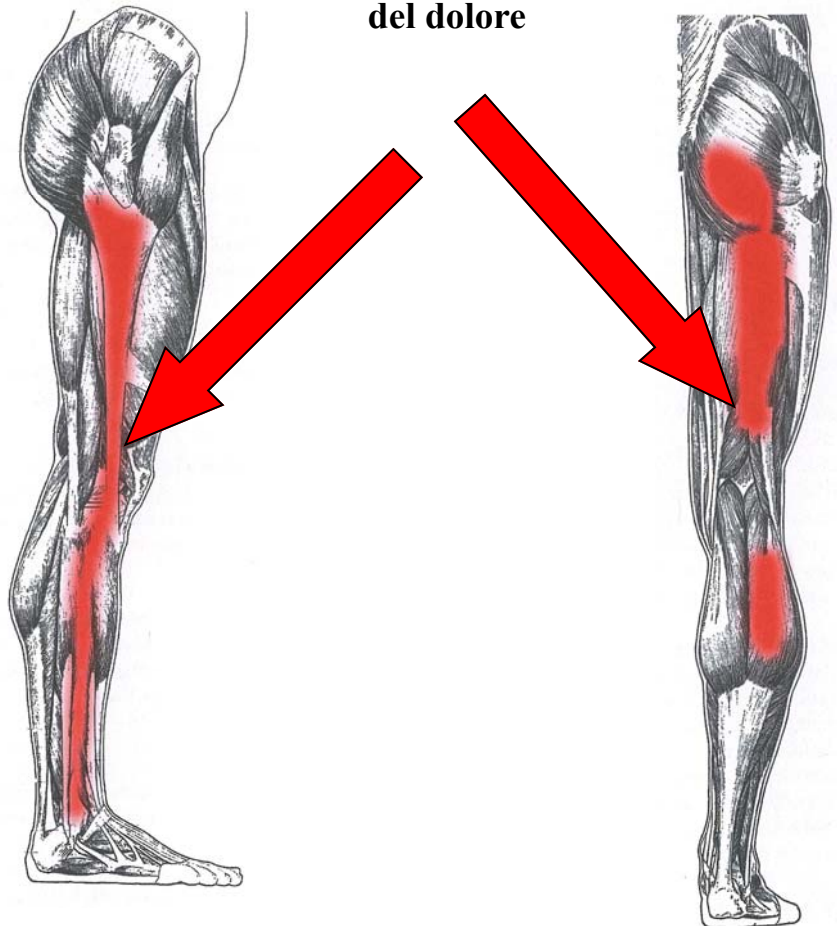


**Schema di propagazione del dolore**

piccolo gluteo

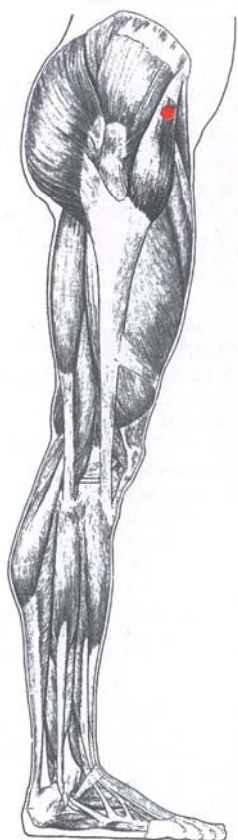


**Il tendine contratto**

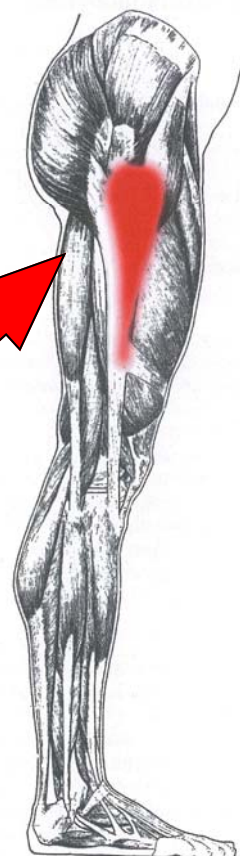

**Schema di propagazione del dolore**

## Tensore della fascia lato




**Il tendine contratto**

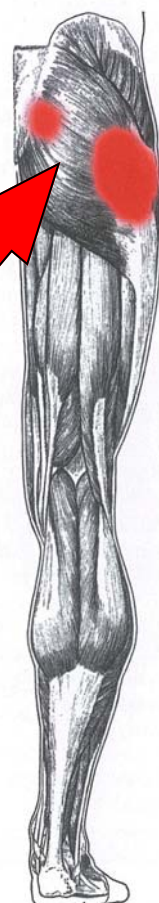

**Schema di propagazione del dolore**

## Piriforme



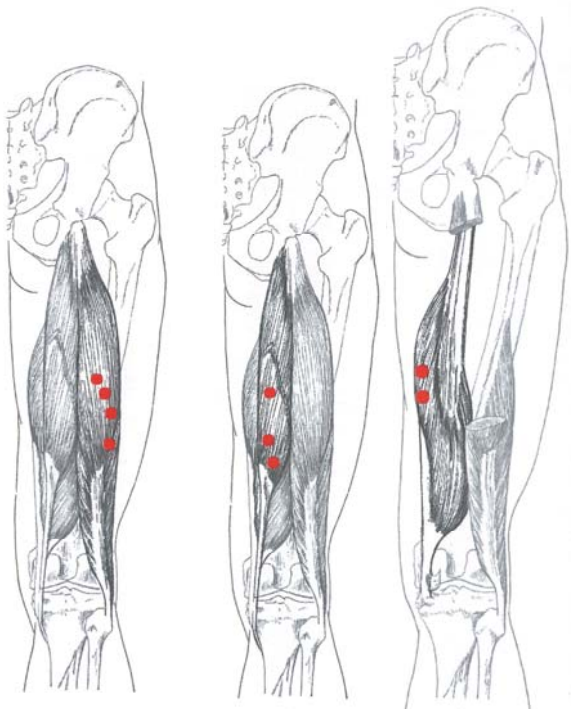
**Il tendine contratto**



**Schema di propagazione del dolore**

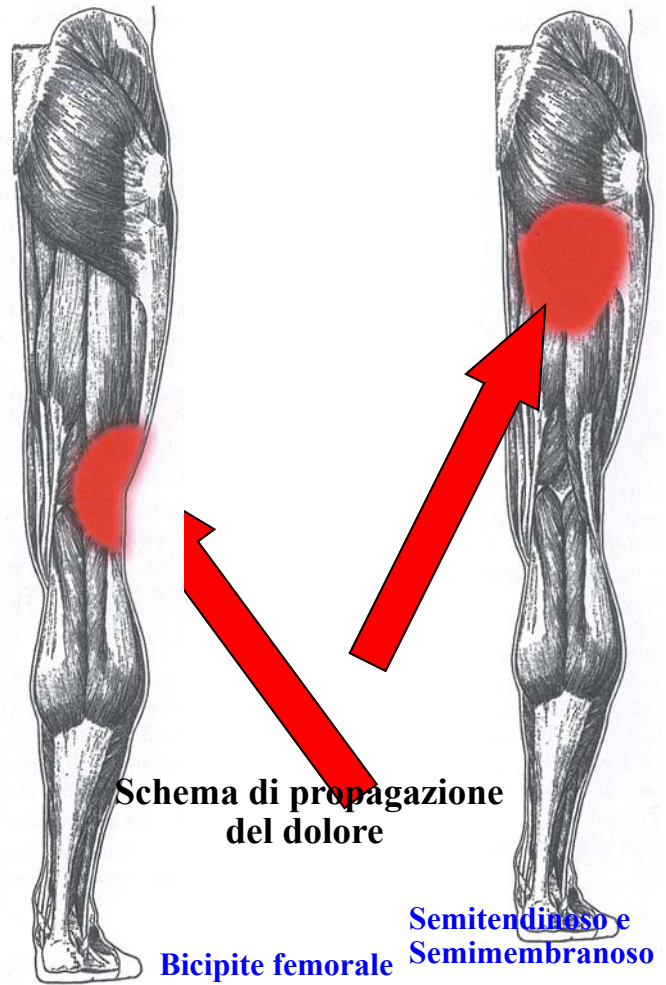
Bicipite femorale

Semimembranoso



Semitendinoso

Il tendine contratto



Schema di propagazione del dolore

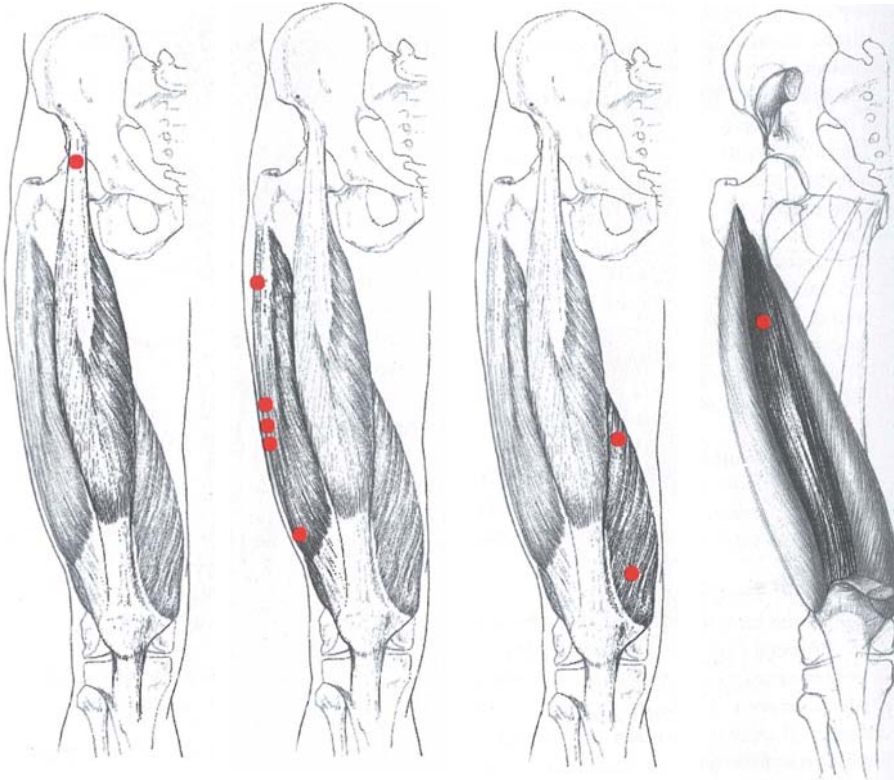
Bicipite femorale Semitendinoso e Semimembranoso

Retto del femore

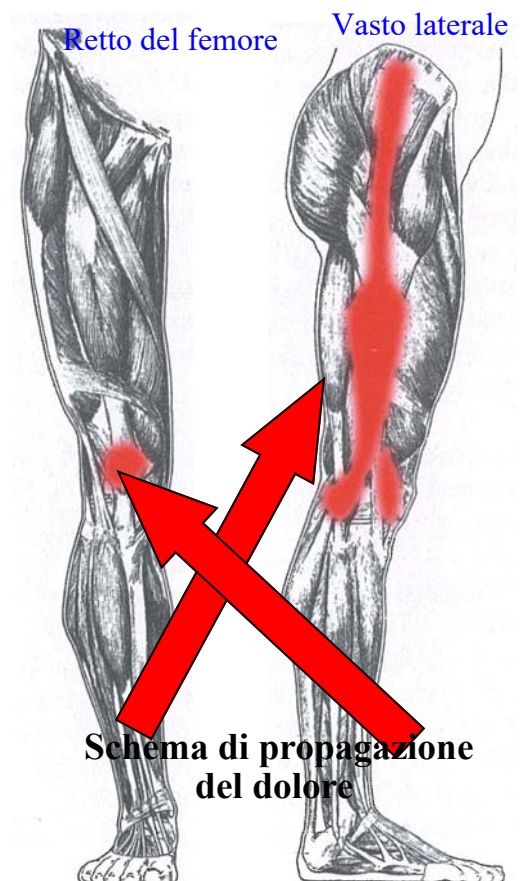
Vasto laterale

Vasto mediale

Vasto interme-



Il tendine contratto



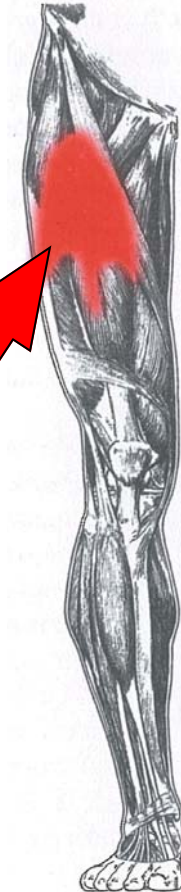
Schema di propagazione del dolore

Retto del femore Vasto laterale

Vasto mediale

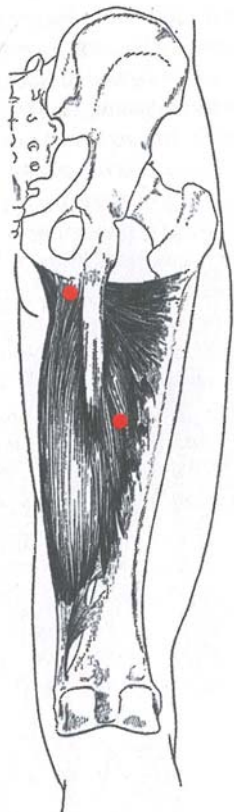


Vasto intermedio

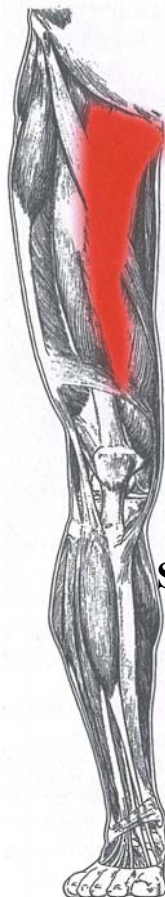

Schema di propagazione del dolore

Grande adduttore

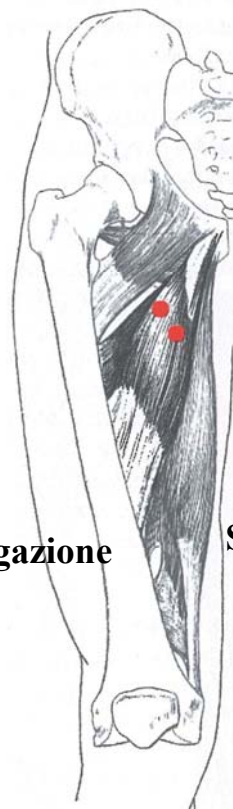


Il tendine contratto

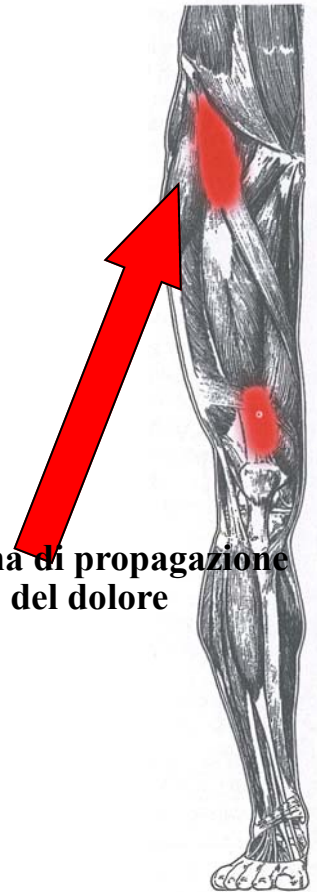

Schema di propagazione del dolore

Adduttore lungo e Adduttore breve



Il tendine contratto



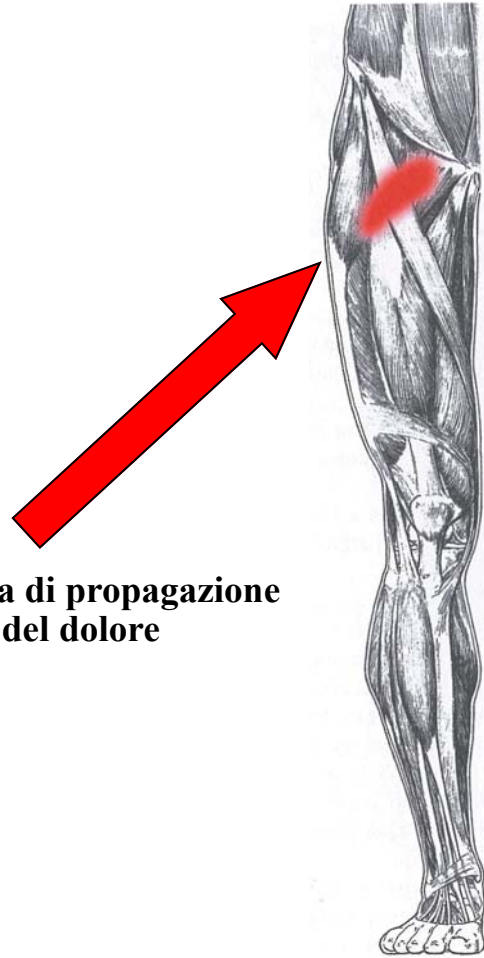
Schema di propagazione del dolore



## Pettineo

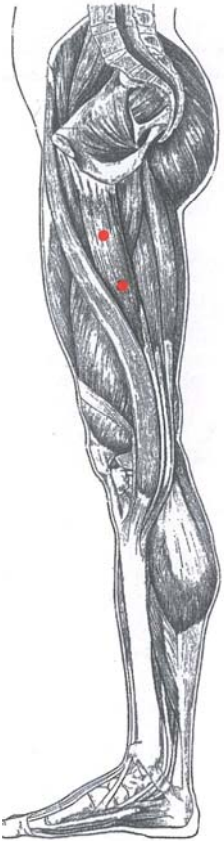

**Il tendine contratto**

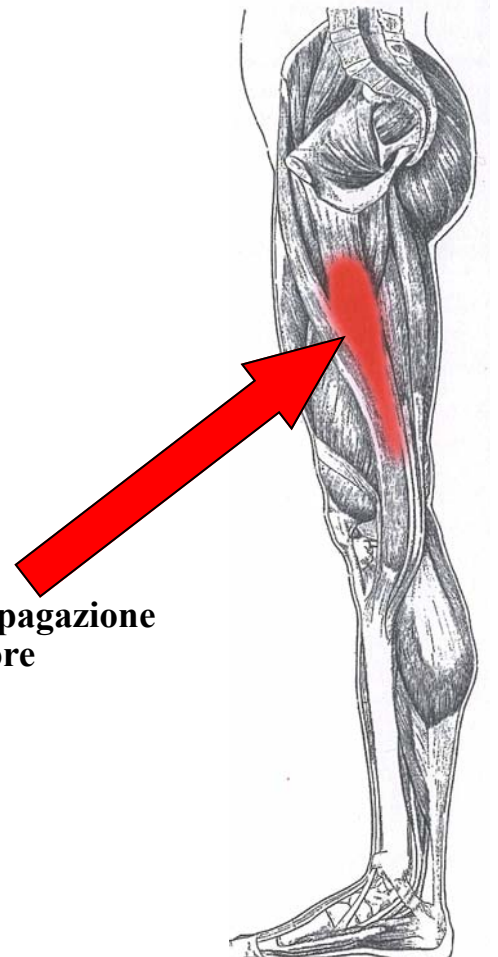


**Schema di propagazione  
del dolore**

## Gracile della coscia

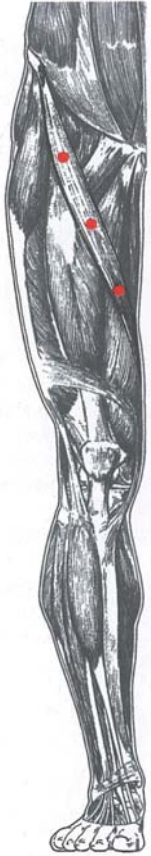

**Il tendine contratto**



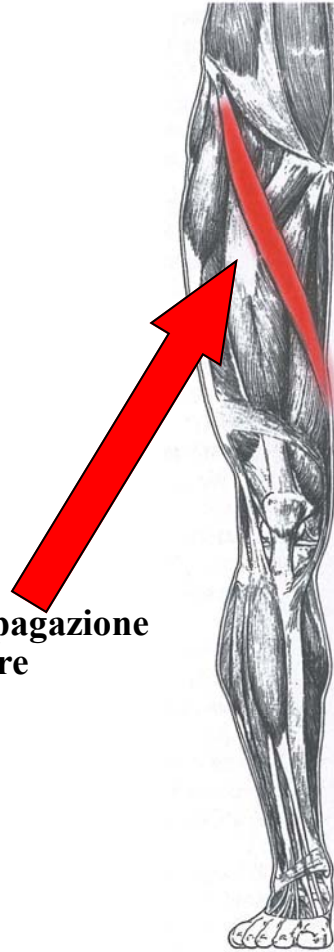**Schema di propagazione  
del dolore**

## Sartorio

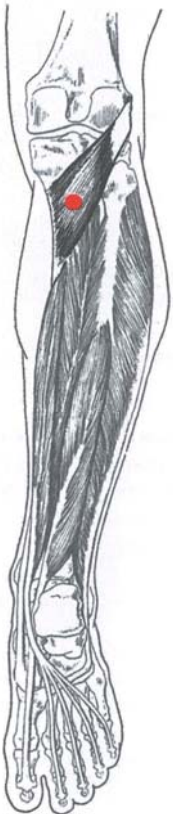

**Il tendine contratto**

**Schema di propagazione  
del dolore**

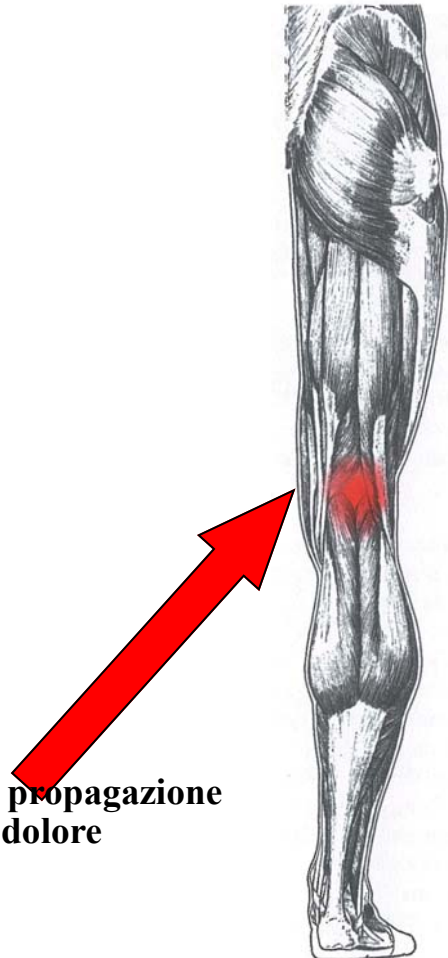


## Popliteo

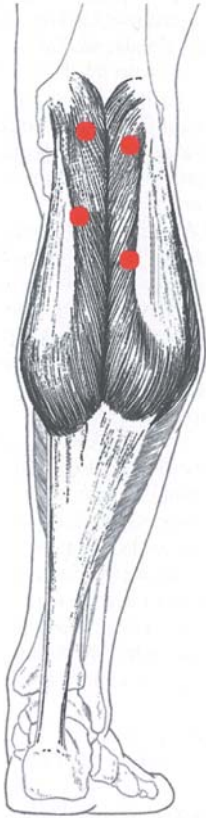


**Il tendine contratto**

**Schema di propagazione  
del dolore**

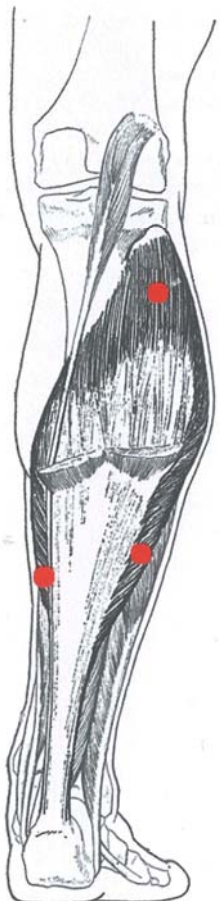
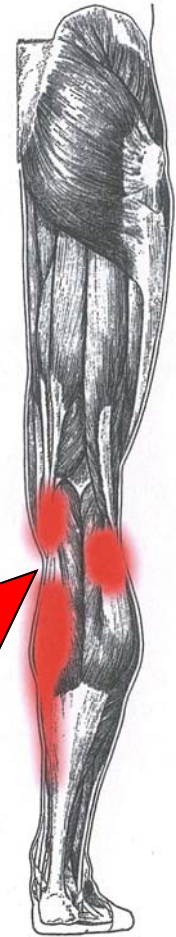

## Gastrocnemio



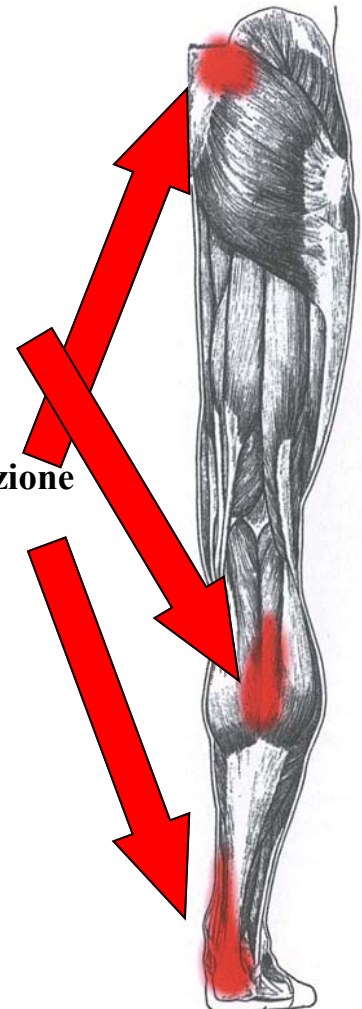**Il tendine contratto**

**Schema di propagazione del dolore**

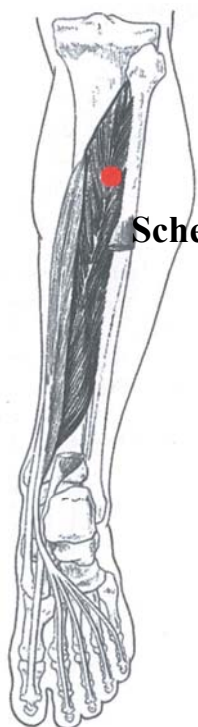


**Il tendine contratto**

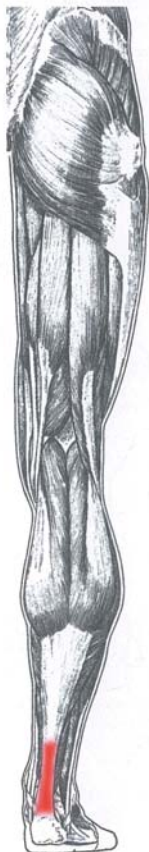
**Schema di propagazione del dolore**



**Tibiale posteriore**

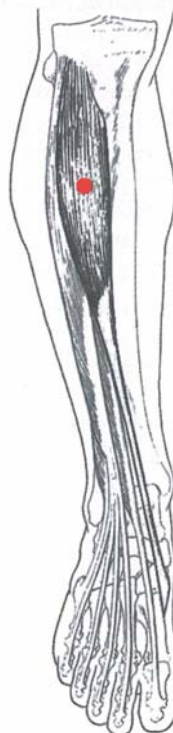

**Schema di propagazione del dolore**

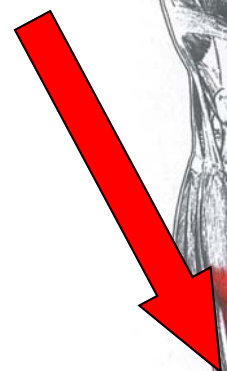

**Il tendine contratto**

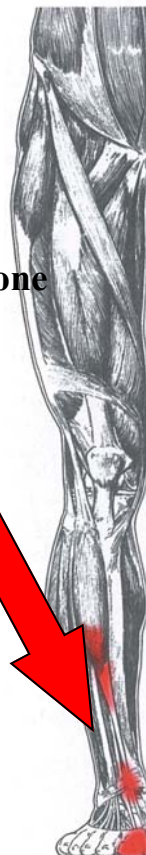**Tibiale anteriore**



**Schema di propagazione del dolore**



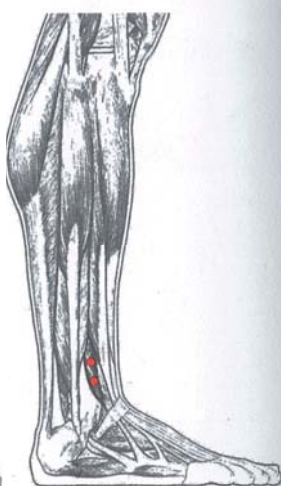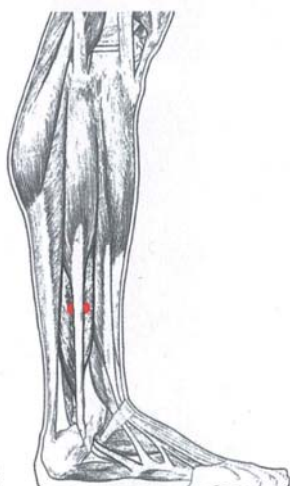
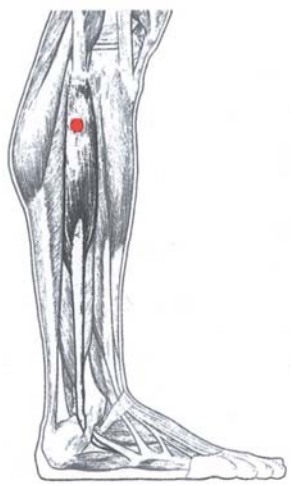
**Il tendine contratto**



**Peroneo lungo**

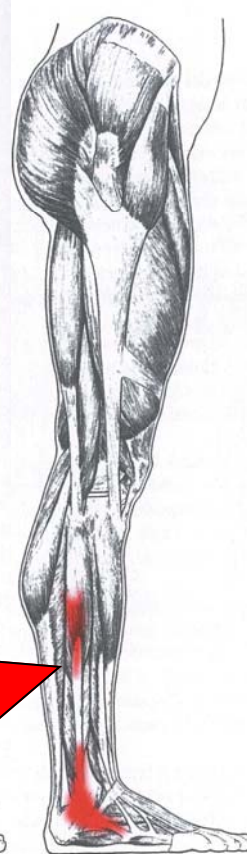
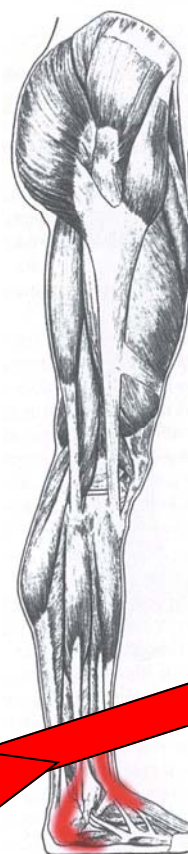
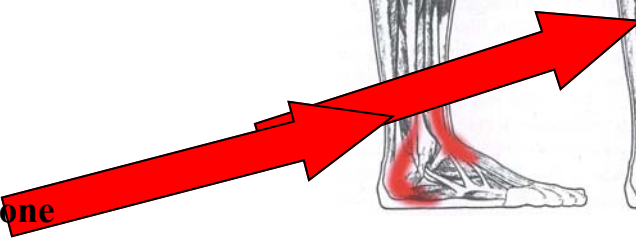
**Peroneo breve**

**Peroneo terzo**

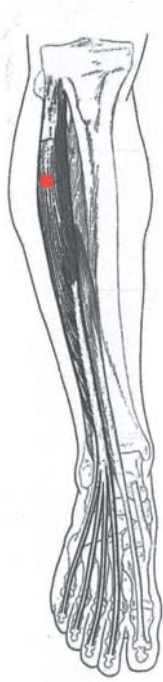

**Il tendine contratto**

**Schema di propagazione del dolore**



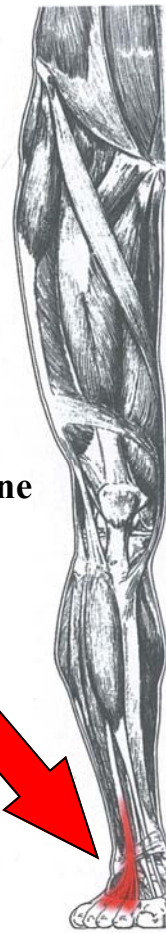**Estensore lungo delle dita**



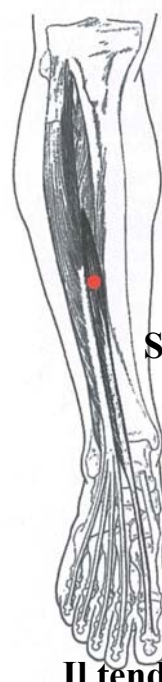**Schema di propagazione del dolore**



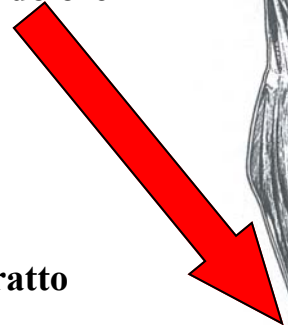**Il tendine contratto**



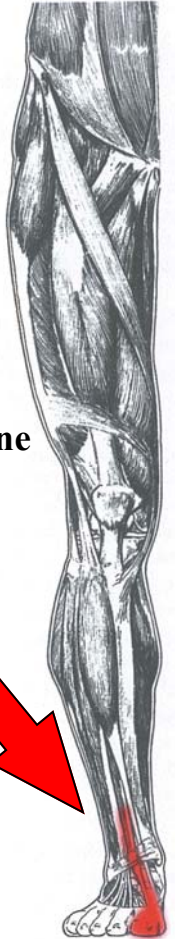**Estensore lungo dell'alluce**



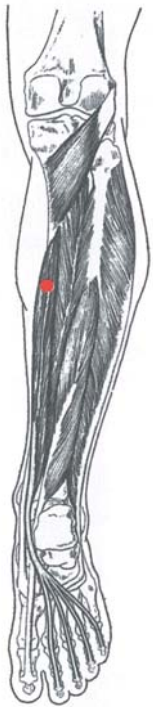**Schema di propagazione del dolore**




**Il tendine contratto**



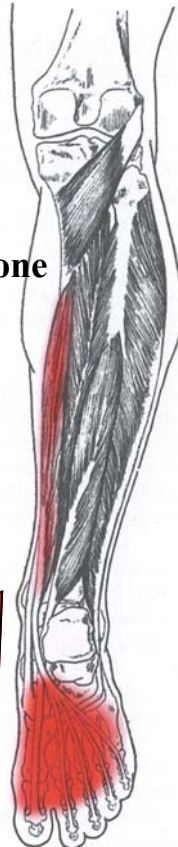**Flessore lungo delle dita dei piedi.**



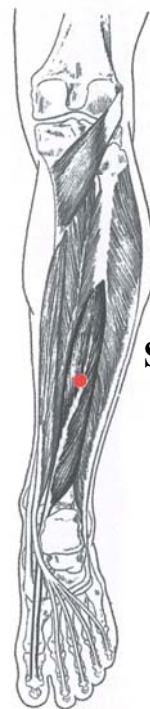**Schema di propagazione del dolore**



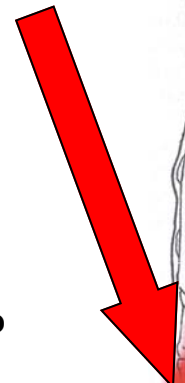
**Il tendine contratto**



**Flessore lungo dell'alluce**



**Schema di propagazione del dolore**



**Il tendine contratto**

